

# We are IntechOpen, the world's leading publisher of Open Access books Built by scientists, for scientists

3,800

Open access books available

116,000

International authors and editors

120M

Downloads

Our authors are among the

154

Countries delivered to

TOP 1%

most cited scientists

12.2%

Contributors from top 500 universities



WEB OF SCIENCE™

Selection of our books indexed in the Book Citation Index  
in Web of Science™ Core Collection (BKCI)

Interested in publishing with us?  
Contact [book.department@intechopen.com](mailto:book.department@intechopen.com)

Numbers displayed above are based on latest data collected.  
For more information visit [www.intechopen.com](http://www.intechopen.com)



---

# Oncoplastic Breast Surgery in the Treatment of Breast Cancer

---

Josie Todd

Additional information is available at the end of the chapter

<http://dx.doi.org/10.5772/intechopen.77955>

---

## Abstract

Breast cancer is one of the commonest cancers affecting women and oncoplastic breast surgery has been firmly established as the mainstay of modern surgical treatment, replacing the traditional two-operation approach. Careful patient selection, relevance of effective communication, patient education and navigating the complex decision-making process, are some of the topics covered in this chapter. Preoperative planning, implant selection, patient marking, importance of scar placement, marking and measuring the patient preoperatively, good theatre practice, technical tips for good cosmesis, and after care; are also discussed. A brief section on revision surgery following implant reconstruction, lipomodelling and a brief overview about breast implant associated anaplastic large cell lymphoma (BIA-ALCL) and multidisciplinary approach to modern management of breast cancer. It aims to serve as a guide to surgeons on current practice and achieving the ideal balance between oncological clearance of the cancer combined with good cosmesis and high levels of patient satisfaction.

**Keywords:** oncoplastic breast surgery, breast cancer, scar placement, patient selection, implant reconstruction, capsular contracture

---

## 1. Introduction

Surgical management of breast cancer has undergone significant evolutionary changes since Halstead's description of radical mastectomy in 1882. Although Halstead was not credited for discovering this technique, his seminal paper published in the *Annals of Surgery* in 1894 demonstrated a 20% survival benefit for the first time. Not surprisingly, the Halstead mastectomy became the standard of care for the next several decades [1]. It took almost 70 years before quadrantectomy was considered a safe alternative to sacrificing the whole breast with long-term follow-up confirmed in the NSABP-B06 and Veronesi's Milan I trial [2, 3].

The term oncoplastic breast surgery (OPBS) was first coined by Werner Audretsch in the 1980s, to describe rearrangement of breast tissue to fill the defect following a partial mastectomy and recreate the breast shape, with emphasis on cosmesis. Over the last three decades, oncoplastic breast surgery has been established globally to encompass the 'quadrant-per-quadrant' approach to breast conservation advocated by Krishna Clough [4] and the Nottingham algorithm for therapeutic mammoplasty, championed by Douglas Macmillan and Stephen McCulley [5]. Introduction of biological mesh or acellular dermal matrix (ADM) in the mid-1990s defined another watershed period with increasing mastectomy rates and immediate reconstruction. Steven Kronowitz from the MD Anderson Cancer Center in Texas, USA, introduced the concept immediate-delayed reconstruction in 2002 to help women avoid the trauma of mastectomy after waking up from surgery [6].

Today, women diagnosed with a new breast cancer are offered a range of treatment options within a multidisciplinary setting [7]. Breast cancer surgery is no longer a two-operation discipline, based on cancer dimension relative to breast size or patient choice of mastectomy versus breast conservation. An oncoplastic approach to modern management of breast cancer involves careful preoperative planning with other specialists such as radiologists, pathologists and oncologists. A comprehensive breast assessment to determine the optimal breast conservation techniques is essential with emphasis on scar placement. All patients undergoing mastectomy should have a discussion around reconstruction options, where appropriate.

Good communication skills and additional time during consultation, helps safeguard patient's understanding of complex discussions around treatment. Early involvement of clinical psychologists in selected cases can help anxious patients and exclude underlying mental health concerns. Heightened anxiety at the time of diagnosis could impact decision-making and alter clinical management, with potential for decision-regret after completing treatment. Well-trained and dedicated breast care nurses are indispensable in a modern surgical breast unit [8]. Providing well designed and simple information leaflets to read outside the stressful environment of the doctor's office, can help patients navigate the complexity of the decision-making process. These combined efforts serve to demystify the various treatment options, empower women with the concept of 'patient choice' and ensure informed consent.

This chapter aims to present aspects of modern oncoplastic surgical approach in the treatment of breast cancer, with emphasis on implant-based reconstruction.

## 2. Oncoplastic breast surgery

Breast conserving surgery, often referred to as lumpectomy or wide local excision (WLE), is the standard treatment for the majority of early invasive and in situ breast cancer [9]. Screening programs have been established for over 60 years with early detection of small and non-palpable cancers, allowing smaller resection volumes and avoiding the need for mastectomy in most women.

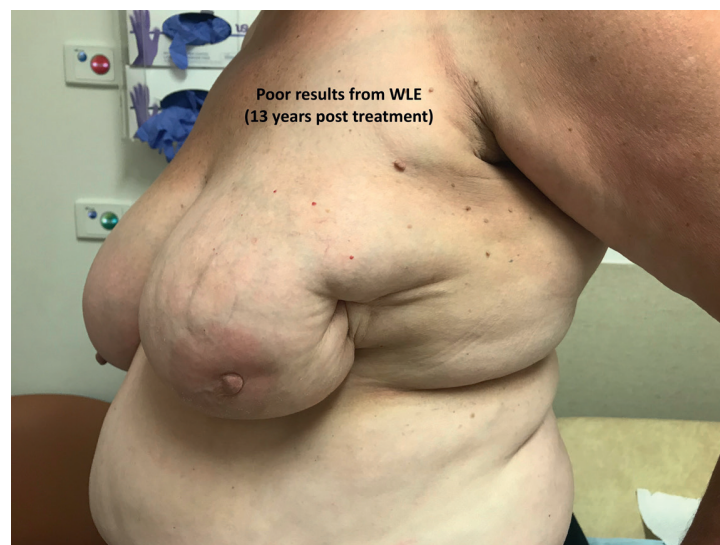### 2.1. Wide local excision (WLE)

Simple excision of the tumour with reasonable margins forms the basis for lumpectomy or wide local excision (WLE) and is appropriate for majority of screen-detected in situ or

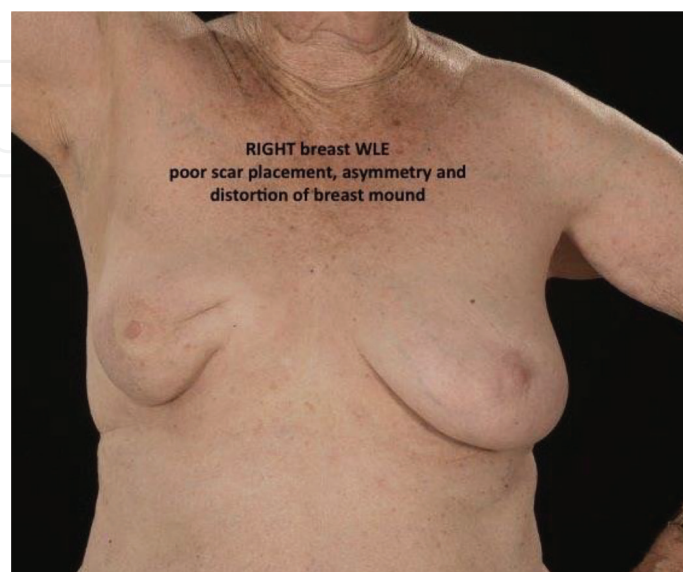
invasive cancer. Traditional approach of scar placement over the tumour site, without adequate mobilisation of skin or approximation of breast parenchyma and leaving the cavity to fill with seroma, was responsible for poor cosmetic outcomes in the past [10]. Volume of excision relative to breast size, location of the tumour and re-excision surgery are independent risk factors for poor cosmesis (**Figure 1**).

In a recent clinical study correlating resection volumes and tumour location with clinical photographs of patients 2 years after completing radiotherapy, was assessed by a panel and scored. Despite the small sample size, there was significant variation in the cosmetic results between oncoplastic surgeon and general breast surgeons (**Figures 2 and 3**) [11].

Oncoplastic breast surgery involves careful preoperative planning with dedicated breast radiologists in the MDT to confirm adequate clearance of the tumour from the overlying skin.



**Figure 1.** Poor cosmetic results from breast conserving surgery.



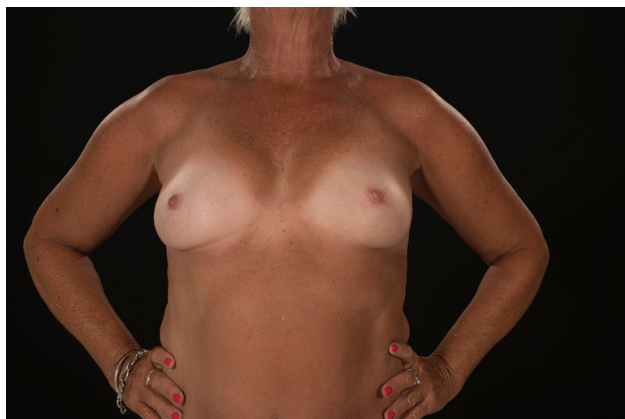**Figure 2.** Clinical study results poor cosmetic outcome.



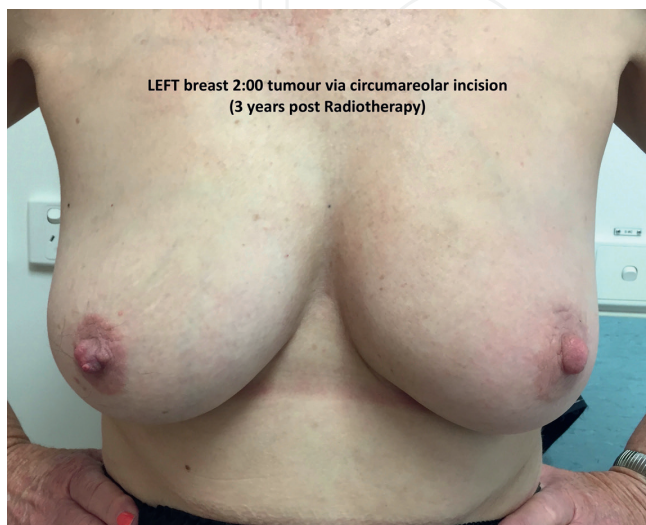This allows aesthetically placed scars which could be remote from the tumour site and avoids disfiguring scars across the breast mound. Mobilisation and approximation of the breast parenchyma after removal of the tumour can help avoid unsightly tethering of the skin to the underlying muscle following radiotherapy (**Figure 4**). These simple measures can help ensure good cosmesis for patients whilst obtaining oncological clearance of the tumour. Almost all cases of wide local excision (WLE) are achievable via a circumareolar approach, which heals well with minimal scarring on the breast mound (**Figure 4**).

## 2.2. Volume displacement techniques

A number of *volume displacement* and *volume replacement* techniques in a *quadrant-per-quadrant approach* to treating breast cancer, have been described by Clough [4]. Careful assessment of the breast size, shape and density combined with preoperative estimation of resection volumes, helps determine the optimal choice of procedure. Two of the commonly used volume displacement techniques, Benelli (round block) and therapeutic mammoplasty, are discussed below.



**Figure 3.** Clinical study results good cosmetic outcome.



**Figure 4.** Wide local excision using circumareolar incision.

### 2.2.1. Benelli/round-block mammoplasty

The Benelli or round-block mammoplasty is a versatile technique used to excise tumours from various quadrants in the breast and reposition the nipple in the desired location at the end of the procedure [12]. This is essentially a variation of the *tennis racquet technique*, but without the 'handle'. The tennis racquet is a useful option if the skin overlying the tumour needs to be excised and prevents the nipple from being tethered towards the index quadrant after radiotherapy and accentuating the asymmetry compared to the contralateral breast. The Benelli mammoplasty can also be used to reduce the skin envelope if required, depending on the volume of resection and the size of the patient's breasts.

Use of bilateral *round-block/Benelli mammoplasty* is illustrated in this 70-year-old patient with aged silicone implants and a new symptomatic LEFT breast cancer. The implants were more than 35 years old with MRI evidence of intra- and extracapsular rupture and silicone leakage (Figure 5). The tumour located in the LEFT breast at 6:00/50 mm from the nipple was excised with safe margins. Capsulectomy and removal of the aged implant was achieved through the same incision and redundant skin excised using the Benelli technique.

MRI proven ruptured aged silicone implant in the opposite breast was also removed via a similar approach with good postoperative symmetry (Figures 6 and 7).

### 2.2.2. Therapeutic mammoplasty (TM)

Adjuvant radiotherapy in large breasted women after WLE can be difficult due to the volume of breast tissue, degree of ptosis and in some cases need to be delivered with the patient prone. *Therapeutic mammoplasty (TM)* combines breast reduction surgery and WLE to provide an opportunity for these women to achieve the desired smaller breasts, as part of their cancer treatment [13]. More importantly, breast reduction surgery after previous radiotherapy increases the risk of wound related complications and should only be undertaken by experienced plastic and oncoplastic breast surgeons. For women with large breasts, TM allows large excision volumes with excellent margins, beyond the conventional threshold for simple

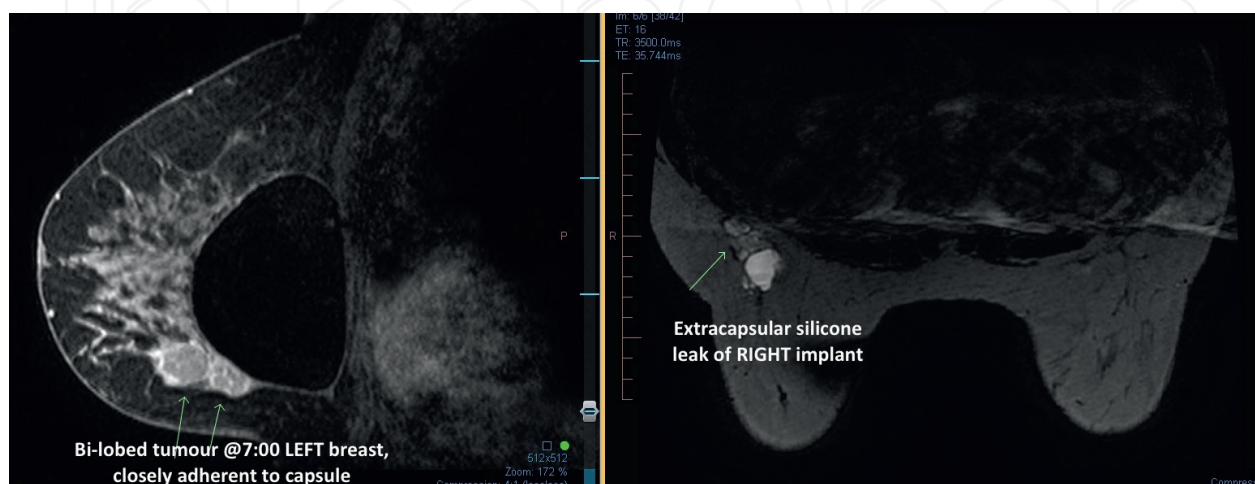
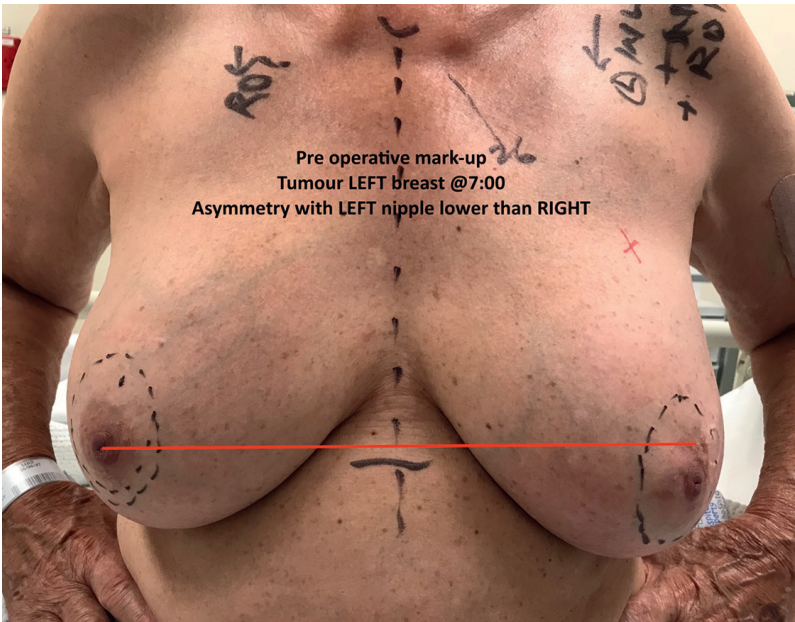
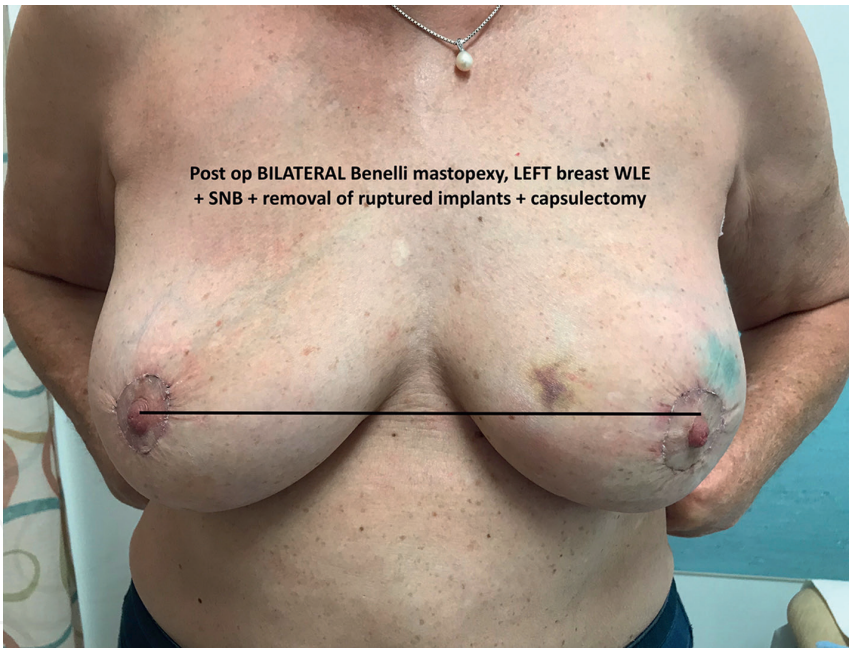


Figure 5. Pre-op MRI demonstrating tumour and silicone leak.



**Figure 6.** Pre-op capsular contracture and Benelli mammoplasty.

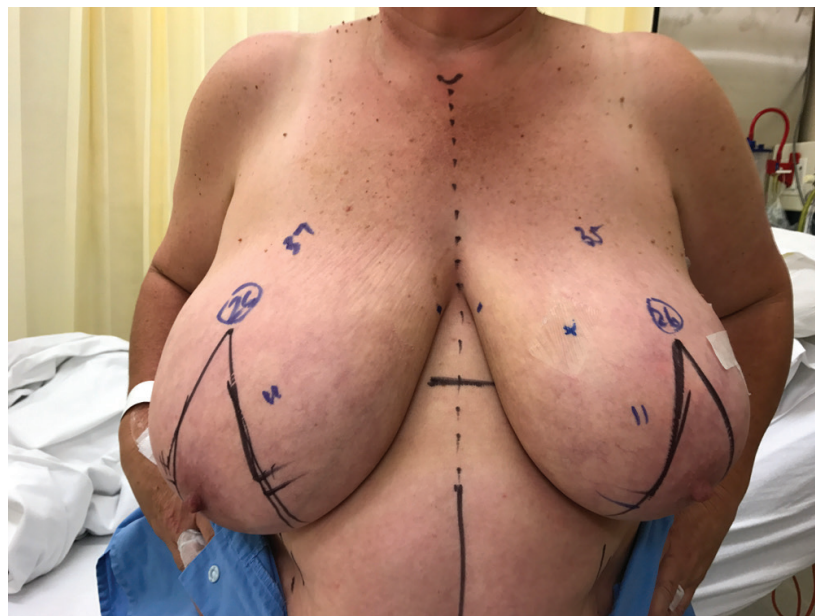


**Figure 7.** Post-op round block mammoplasty.

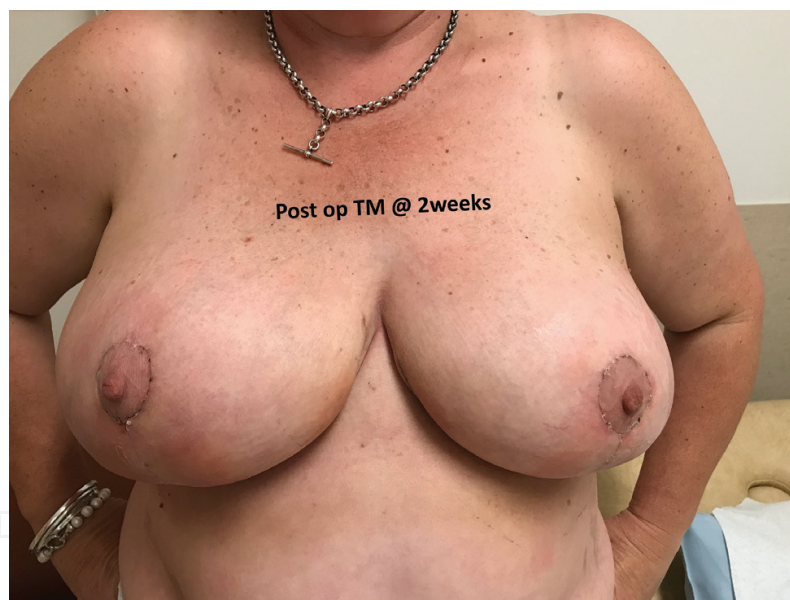WLE. Secondary pedicles of tissue which are usually excised as part of breast reduction surgery are used to fill the WLE defect. Recovery from surgery is similar to simple mastectomy without any delay in adjuvant therapy (**Figures 8 and 9**).

The nipple-areolar complex (NAC) can be sacrificed in older patients to minimise the risk of nipple necrosis and wound complications. The NAC may also need to be removed when the tumour is located close to the nipple to ensure oncological safe margins. TM in this setting





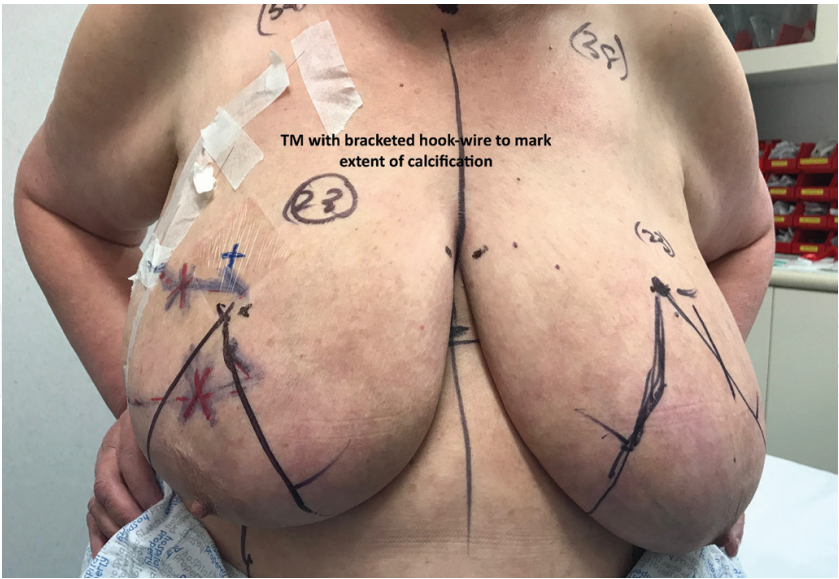
**Figure 8.** Pre-op therapeutic mammoplasty.



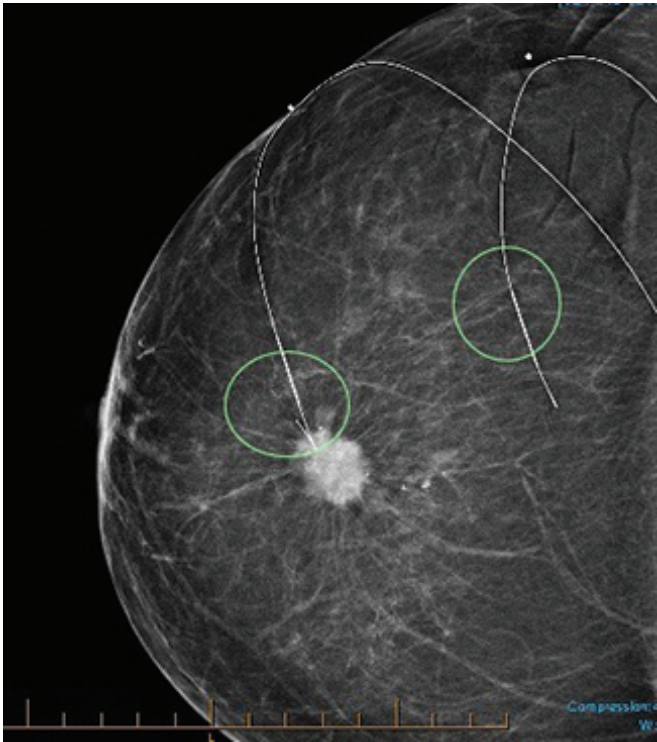
**Figure 9.** Post-op therapeutic mammoplasty.

provides a better alternative to mastectomy for these patients and avoids large and heavy external prosthesis to match the contralateral normal breast [14]. In this example, an 83-year-old lady with large ptotic J-cup sized breasts presented with symptomatic 45 mm RIGHT breast cancer @12:00, with associated 110 mm of suspicious calcification extending to the nipple (**Figure 10**).

Bracketed hook-wire was used preoperatively to mark the extent of calcification to ensure safe margins and confirmed on final histology (**Figure 11**). Despite the extensive nature of surgery,



**Figure 10.** Pre-op hook-wire and markings for TM.



**Figure 11.** Bracketed hook-wire.

TM confers a high degree of patient satisfaction, without any delay in adjuvant treatment or significant morbidity; even in older patients (**Figure 12**). Well-trained breast care nurses are essential for preoperative patient education and managing complex wounds after surgery.

**2.3. Volume replacement techniques**

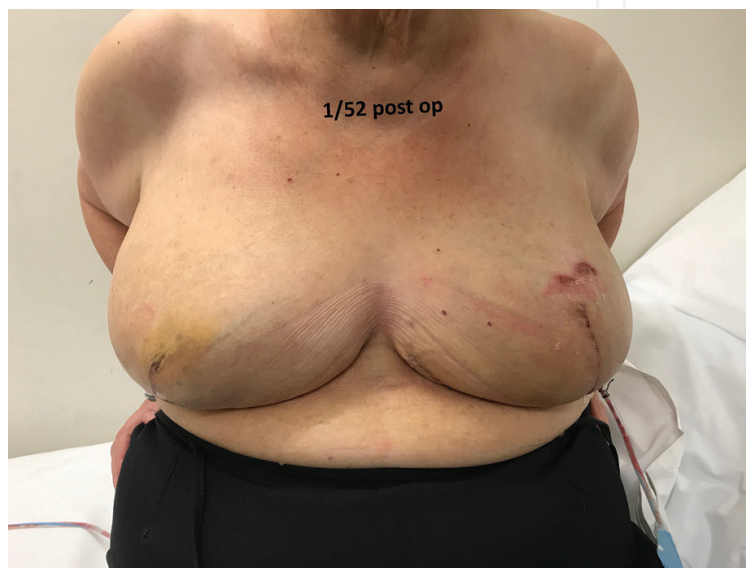Several volume replacement techniques, such as mini-latissimus dorsi (LD), lateral thoracic artery perforator (L-TAP), intercostal artery perforators (I-CAP), serratus anterior artery perforator



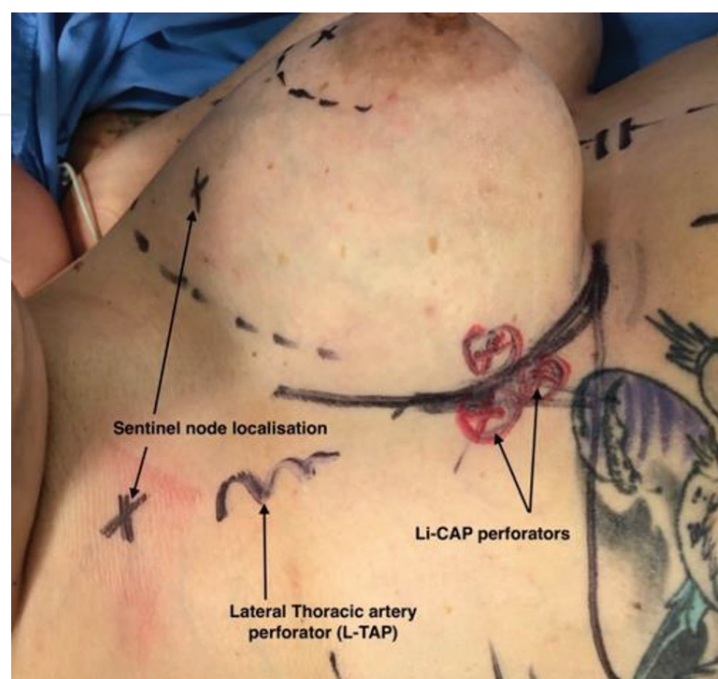
(SAAP) and thoracodorsal artery perforator (T-DAP) flaps have been described to fill large defects created by WLE. Mini-LD flaps should be avoided in this setting and the latissimus dorsi muscle preserved as salvage tissue cover for complex locally advanced and recurrent disease, for lower pole support instead of mesh or as definitive reconstruction option following mastectomy.

### 2.3.1. Autologous adipo-dermal perforator flaps

The original pedicled perforator flaps described by Mustafa Hamdi in 1984 included thoracodorsal artery perforator (T-DAP), intercostal artery perforator (ICAP), serratus anterior



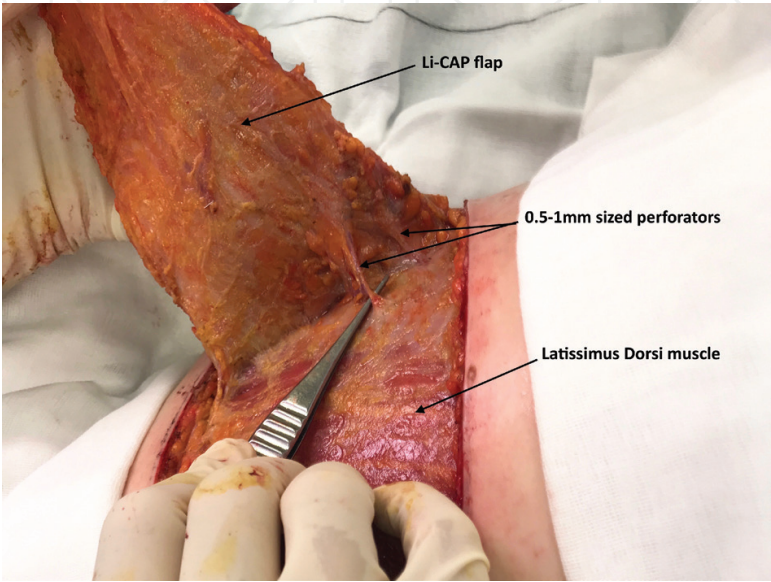
**Figure 12.** Post-op TM sacrificing the NAC.



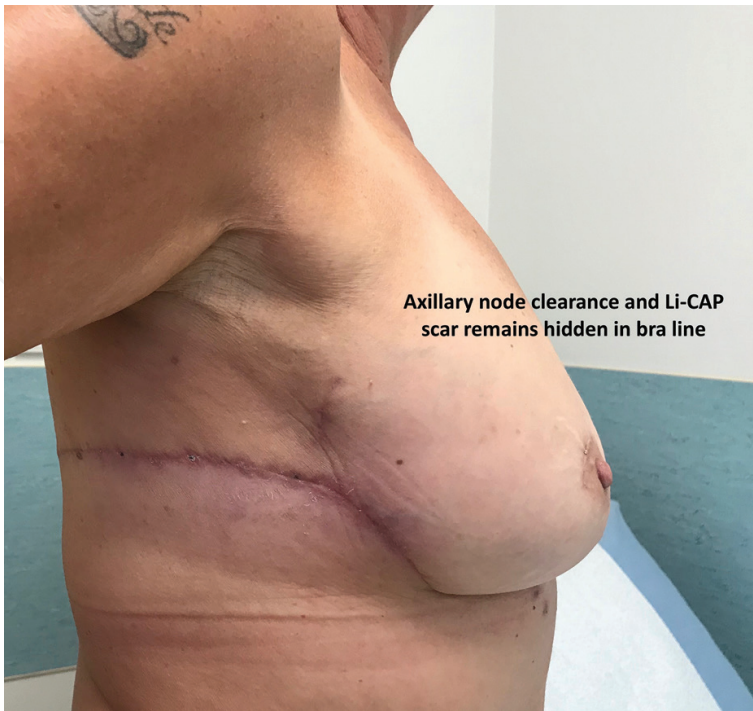**Figure 13.** Pre-op marking of L-TAP and Li-CAP vessels with USS Doppler.

artery perforator (SAAP) and superior epigastric artery perforator (SEAP) flaps for immediate or delayed partial breast reconstruction or as adjuncts to implant reconstruction [15]. These versatile perforator flaps can be used to fill parenchymal defects in almost any quadrant of the breast. This technique allows large excision volumes to ensure good resection margins and the size of the flap can be adjusted to achieve good cosmesis.

The Li-CAP and T-DAP vessels are marked preoperatively with handheld Doppler’s or USS colour Doppler mode prior to skin incision (**Figure 13**). These flaps utilise the skin and subcutaneous fat in the lateral chest wall and are raised on small and consistent perforator vessels (**Figure 14**).



**Figure 14.** Perforator vessels for Li-CAP flap.

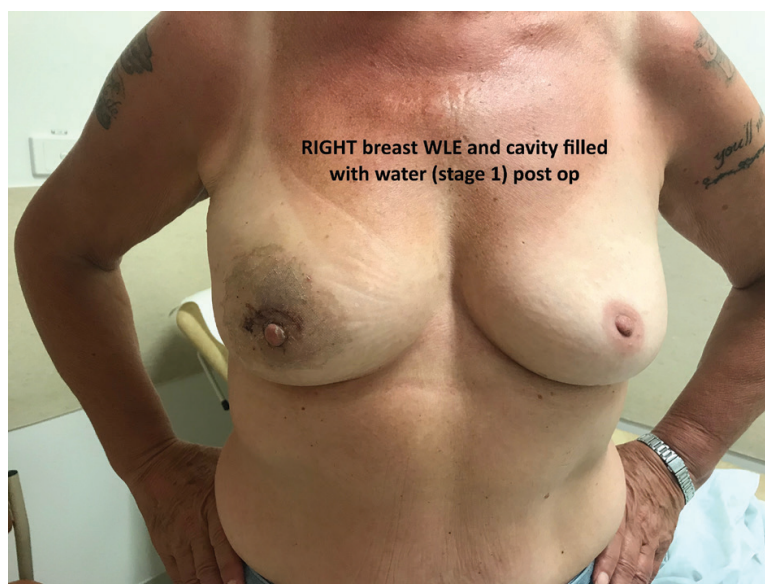

**Figure 15.** Lateral scar after volume replacement with Li-CAP flap.

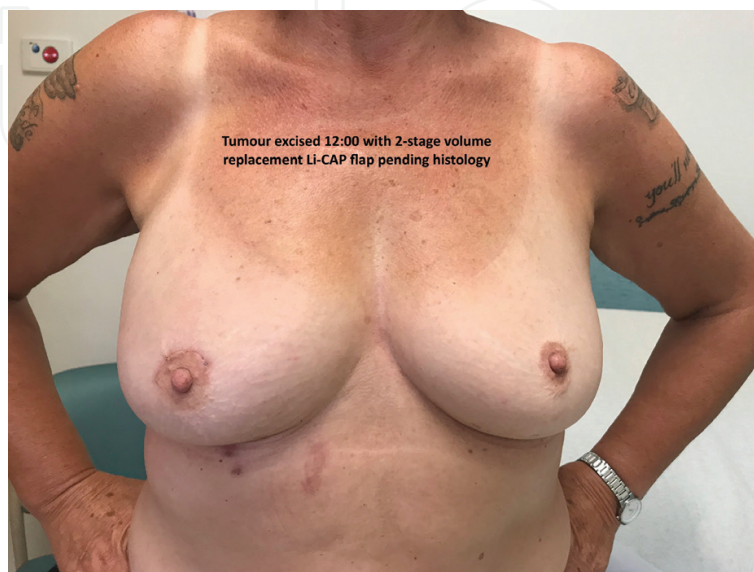

The length of the scar is variable depending on the volume required for replacement and is mostly hidden within the bra, with less donor site morbidity compared to traditional LD flap (**Figure 15**). These autologous perforator flaps are robust and appear to tolerate radiation therapy without significant volume loss. They serve as ideal volume replacement options for high-risk patients such as diabetics, smokers and older patients, without compromising flap viability.

Two-stage procedure is recommended by the Nottingham group, particularly if the extent of disease is unclear on diagnostic imaging. WLE and axillary surgery is completed as the first stage and the cavity filled with water to keep the cavity patent. Once the histology confirms adequate margins, patients can undergo the second stage to recruit the perforator flap (**Figures 16 and 17**). If the pathology demonstrates more extensive disease than originally



**Figure 16.** After first stage WLE cavity filled with water.



**Figure 17.** Post-op photo after volume replacement with Li-CAP.

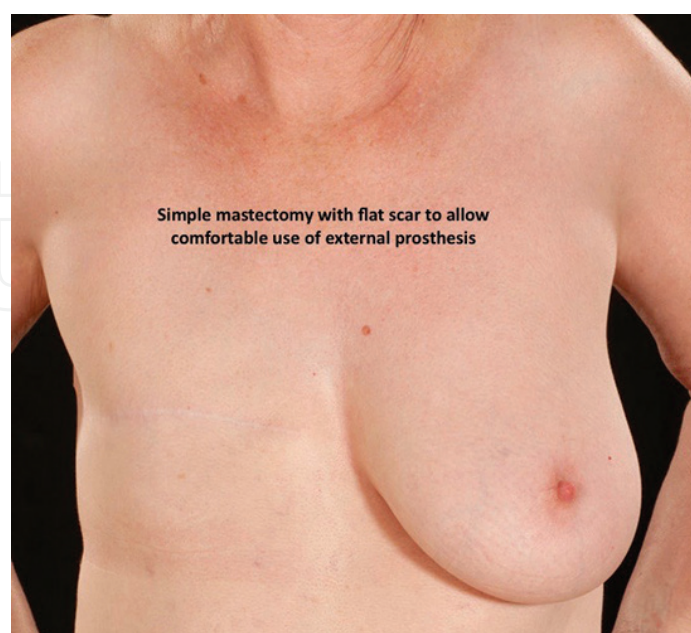
anticipated, patients could be offered re-excision of margins or conversion to mastectomy. A two-stage procedure helps avoid wasting a good flap in the initial stage and serves as a bridge to definitive surgery.

### 3. Mastectomy and breast reconstruction

Simple mastectomy is a good surgical option for elderly patients, women living in remote areas with limited access to radiotherapy and those who do not wish to undergo immediate reconstruction (**Figure 18**). Increasing number of women is choosing to have mastectomy with immediate reconstruction instead of breast conservation [16].

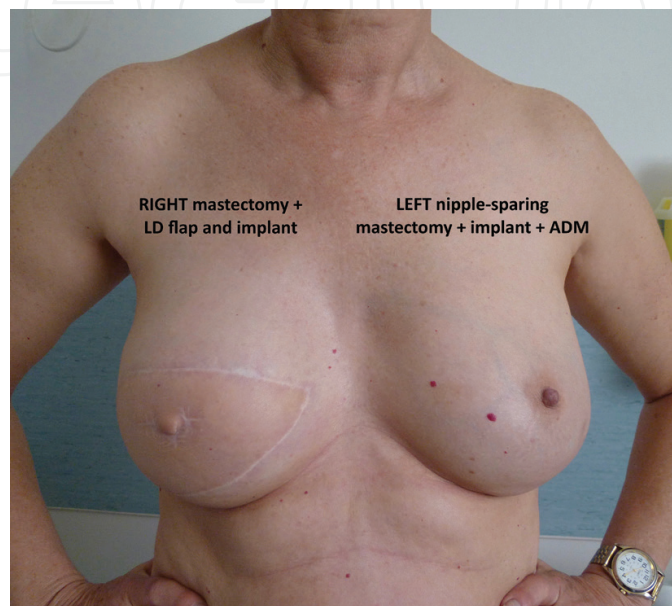
'A good reconstruction starts with a good mastectomy' is an often quoted by oncoplastic breast surgeons and advocated by the Nottingham Breast Unit, UK. Historically, free-transverse rectus abdominis (TRAM) flap or deep inferior epigastric artery perforator (DIEP) flap has been regarded as the gold standard for breast reconstruction [17]. This is a significant undertaking for patients with prolonged hospital stay, delayed recovery and donor site morbidity. Not surprisingly, the incidence of these complex autologous flaps has remained static compared to the exponential increase in implant reconstruction over the past three decades [18].

Latissimus dorsi (LD) flap with implant (**Figure 19**) was a common reconstruction procedure post mastectomy in the 1980s and 1990s, due to the robust nature of the flap, consistent aesthetic results and acceptable donor site morbidity compared to TRAM flap. The incidence of LD has declined with the increasing incidence of implant reconstruction in the late 1990s and early 2000s. More recently, there appears to be a resurgence of LD flaps, according to MD Anderson data [18].

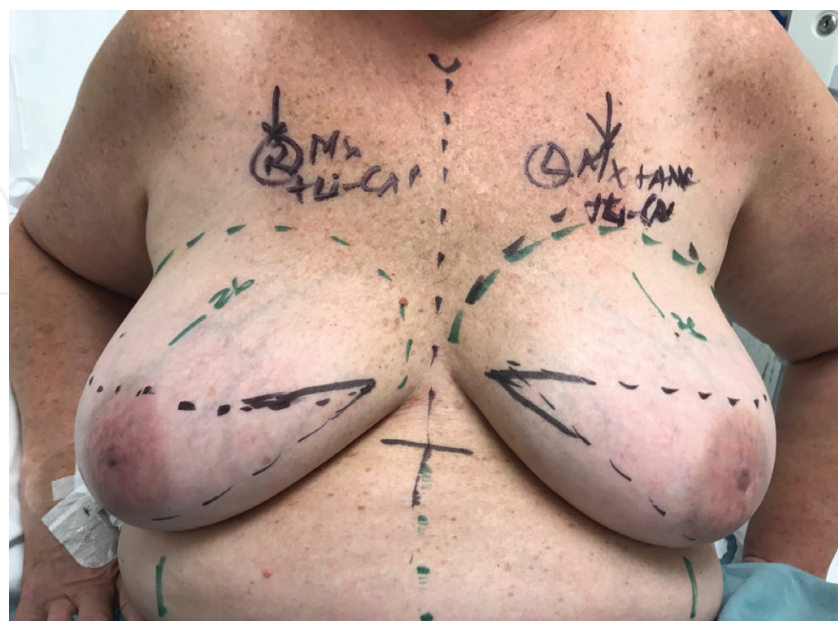

**Figure 18.** Right simple mastectomy.

The chest wall perforator flaps (L-TAP and Li-CAP) can also be used as complete autologous flap reconstruction following mastectomy and was first described by Losken and Hamdi in 2009 [19, 20]. This is a safe reconstruction option in the high-risk candidates, such as smokers, raised BMI, diabetics, or in patients where implant or complex autologous reconstructions are relatively contraindicated due to post-operative radiotherapy (Figures 20 and 21).

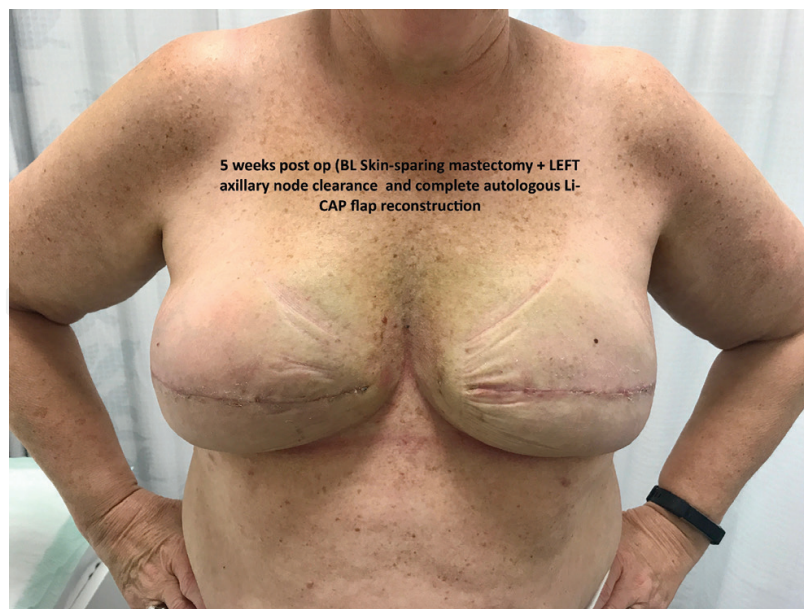

**Figure 19.** Right mastectomy with immediate LD flap and left mastectomy with implant reconstruction.



**Figure 20.** Pre-op marking bilateral mastectomy following neoadjuvant chemotherapy.





**Figure 21.** Post-op bilateral skin-sparing mastectomy with immediate Li-CAP flap reconstruction.

#### 4. Mesh versus autologous tissue for lower pole support

Since its introduction in the late 1990s, the acellular dermal matrix (ADM), derived from various biological sources, has been responsible for the meteoric rise in mastectomy rates with implant and tissue expander reconstruction [21]. There is a substantial global market for ADM or biological meshes currently manufactured from porcine dermis, foetal or neonatal bovine dermis, bovine pericardium and human cadaveric skin.

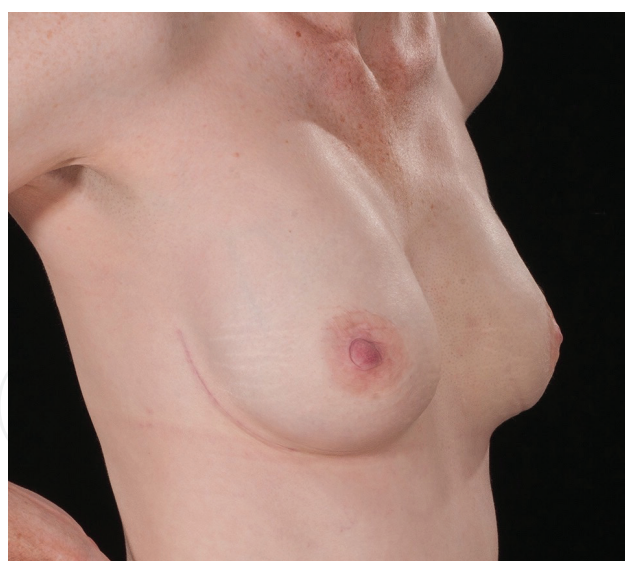
Parallel to the success of ADM, there has also been an increase in synthetic mesh used for lower pole support in implant and tissue expander reconstruction (**Table 1**). The main driver for synthetic mesh has stemmed from cost associated with ADM, reports of 'red breast syndrome' (RBS) and higher seroma rates [22]. The 'red breast syndrome' (RBS) is a unique delayed hypersensitivity reaction to ADM and presents as erythematous skin overlying the mesh. Despite lack of febrile response and normal laboratory markers which characterises RBS, patients often receive increasing amounts of unnecessary antibiotics, due to concerns for the underlying implant [23].

The absorbable synthetic TIGR mesh produces a stable IMF after 18 months post-reconstruction compared to ADM with lower implant loss rates and half the volume of seroma output in the author's experience (**Figure 22**) [24].

In one of the largest reported series of TIGR mesh since May 2014, a total of 138 cases in 87 consecutive patients undergoing immediate or delayed reconstruction were recently presented in the Annual Scientific Congress of RACS (Royal Australasian College of Surgeons) in Sydney, Australia, in May 2018. There was no 90-day post-operative implant loss reported in the author's series, with three cases of delayed implant loss at 5, 12 and 28 months following radiotherapy. There were no cases of skin flap necrosis or RBS in this series [25]. These results

Mesh	ADM/synthetic	Source	Manufacturer
Strattice	ADM	Porcine	LifeCell Corp.
Permacol	ADM	Porcine	Covidien
SurgiMend	ADM	Foetal/neonatal bovine dermis	Integra LifeScience Ltd.
VERITAS	ADM	Bovine pericardium	Synovis Surgical innovations, St. Paul, MN, USA®
Alloderm	ADM	Human cadaveric skin	LifeCell Corp. Branchburg, N.J
Epiflex	ADM	Human cadaveric skin	Deutsches Institut für Zell-und Gewebeersatz [DIZG] gGmbH, Berlin, Germany
ALLOMAX™	ADM	Human cadaveric skin	Bard, Inc.
DermaMatrix®	ADM	Human cadaveric skin	Synthesis CMF/Johnson & Johnson
TIGR	Synthetic absorbable		Novus Scientific
TiLoop® Bra	Synthetic titanium coated		pfm medical, Cologne, Germany
SERAGYN BR®	Synthetic		SERAG-WIESSNER GmbH & Co. KG

**Table 1.** Current list of ADM and synthetic mesh used for implant and tissue expander reconstruction.



**Figure 22.** Nipple-sparing mastectomy via inframammary fold incision and retropectoral implant reconstruction and TIGR mesh.

are similar to a recent publication by Pompei et al., with 49 consecutive patients and 60 TIGR mesh used over a 2-year period with only 1 implant loss due to skin necrosis [26].

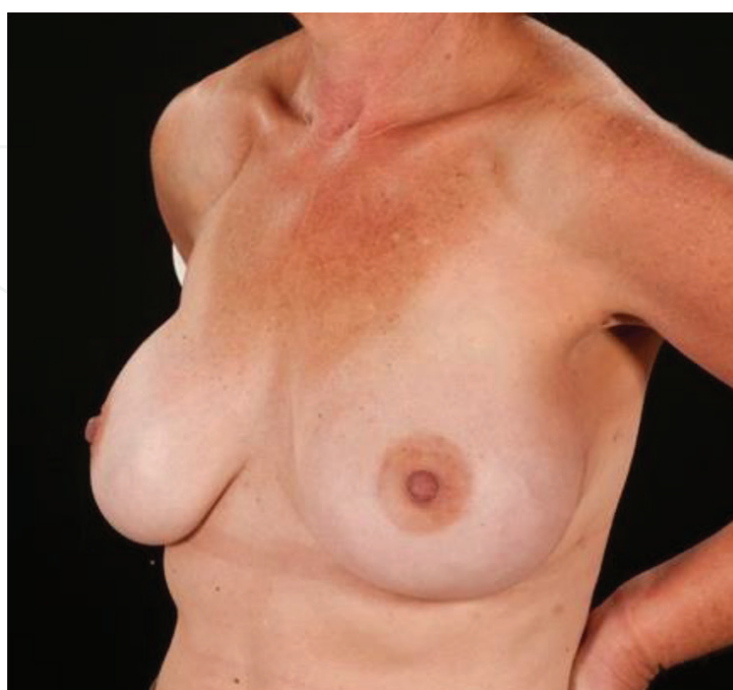The following is the example of nipple-sparing mastectomy, axillary node clearance with immediate expander-implant reconstruction in a 54-year-old woman with previous breast

implants and multifocal triple negative breast cancer with nodal involvement (**Figures 23–25**). Patient developed significant lymphangitis and cellulitis of the breast skin envelope 28 months after radiotherapy with explantation and request for contralateral symmetrising mastectomy.

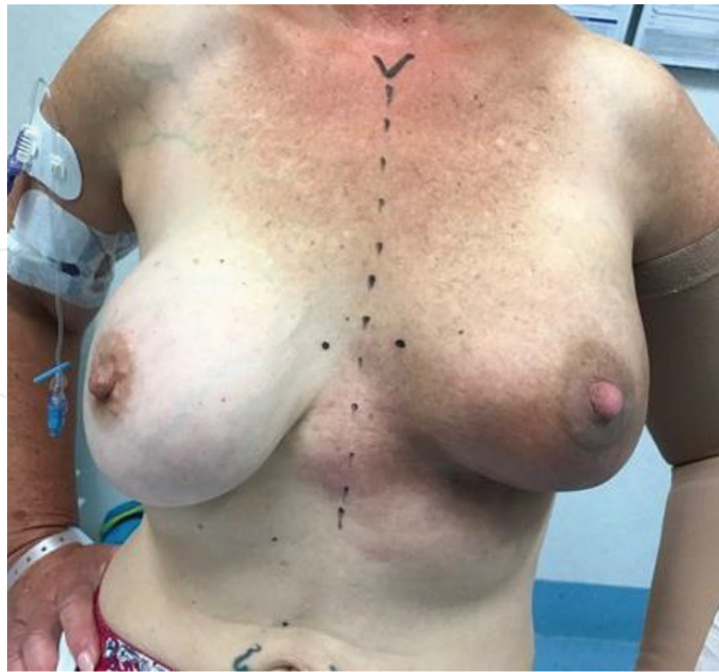The two-stage tissue expander (TE) reconstruction with limited mobilisation of the serratus muscle and pectoralis major was the standard procedure prior to ADM or synthetic mesh for lower pole support. The results were often inconsistent with high-riding TE and need for revision surgery. The nipple-areolar complex (NAC) and most of the redundant mastectomy skin envelope in medium to large breasted women had to be sacrificed due to limited capacity of the muscle pocket. Stable inframammary fold (IMF), preservation of the native mastectomy skin flap, retropectoral direct to implant reconstruction with predictable aesthetic results and relatively short learning curve; are some of the reasons for the exponential global uptake of biological and synthetic mesh. Shorter operative time and hospital stay, earlier recovery and return to normal function with less donor site morbidity and high patient satisfaction rates have also contributed to its popularity.

More recently, use of prepectoral implant with complete ADM coverage appears to have good outcomes with high levels of patient satisfaction [27]. ‘Animation’ or variable movement of the reconstructed breast when tensing the pectoral muscles is a recognised issue with retropectoral implant reconstruction (Video: <https://mts.intechopen.com/download/index/process/270/authkey/a5ea41ce666a3344dd2e459c34b3d46a>). The prepectoral technique circumvents the ‘animation’ problem and patients are able to return to physical activity without the usual restrictions of retropectoral surgery.

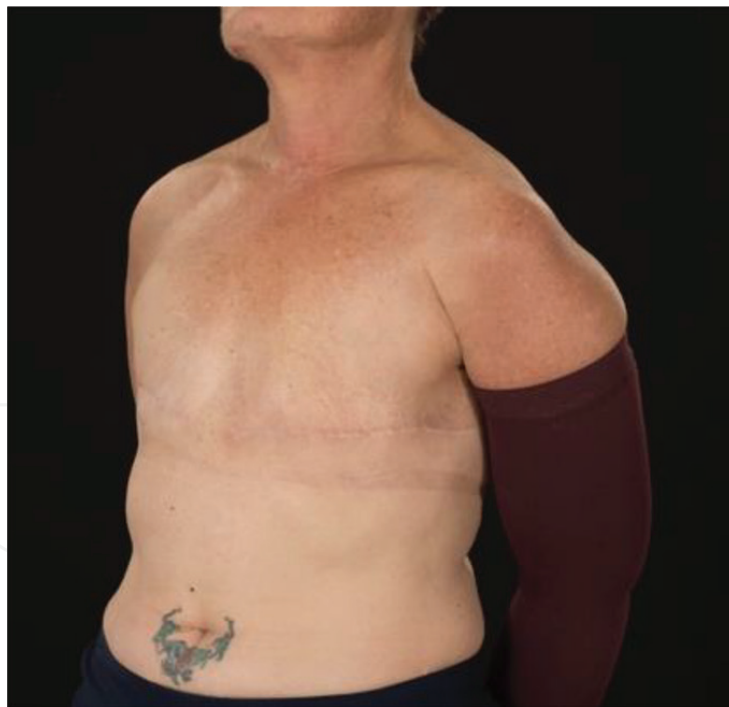Any contour defect due to capsular contracture or tethering of skin to the pectoral fascia above the implant, can be addressed with fat grafting; either at the index operation or as



**Figure 23.** Left nipple-sparing mastectomy with immediate expander-implant reconstruction.



**Figure 24.** Cellulitis 28 months after radiotherapy.



**Figure 25.** Bilateral mastectomy post explantation and request for delayed reconstruction.

a delayed procedure. In very slim patients without significant subcutaneous body fat, prepectoral approach may be challenging with 'ghosting' effect from the underlying implant. Braxon ADM (designed and patented by DECOMED s.r.l.) is a specially designed biological mesh, which offers complete coverage of the implant for prepectoral placement with the added convenience of suturing the mesh directly onto the chest wall.

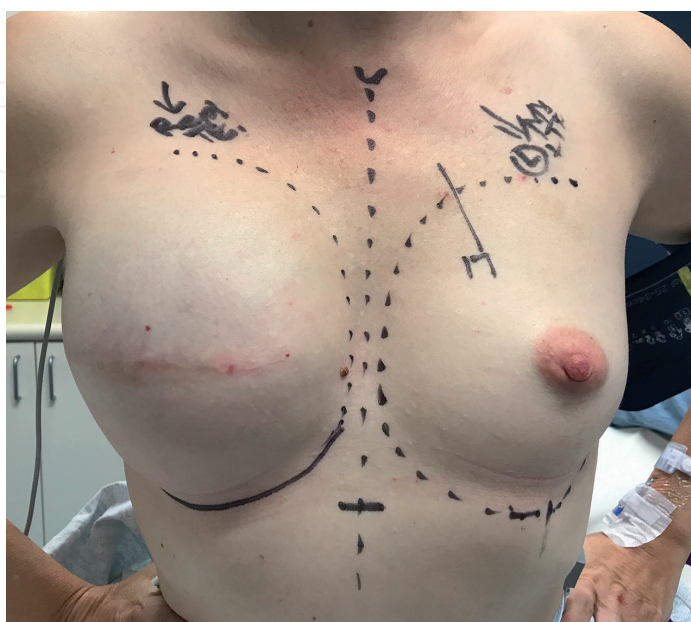


Despite the significant global trend towards ADM and synthetic mesh-assisted implant reconstruction, recent years have also witnessed a resurgence in autologous tissue for inferior pole support, such as scar-less mini-LD flap and T-DAP flap. ADM associated 'red breast syndrome RBS', less than anticipated reduction in capsular contracture, higher seroma rates and secondary infection with implant loss; may account for this parallel rise in autologous tissue support. Some permanent synthetic meshes can result in higher rates of capsular contracture with firm tissue in the lower pole, resulting in long-term discomfort. Continued technological advances in lightweight synthetic mesh which integrate better with the host tissue, could help improve cosmetic outcomes for patients.

## 5. Tissue expander versus direct to implant reconstruction

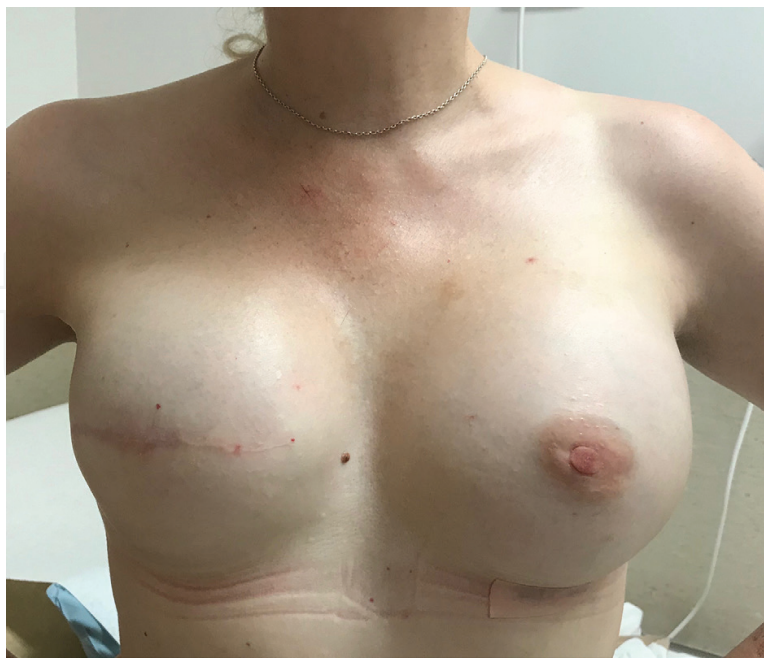The two-stage tissue expander (TE) is the standard reconstruction technique following skin-sparing or nipple-sparing mastectomy in most Western countries. TE is a safer option than direct to implant, particularly when there is uncertainty about the need for post-operative radiotherapy. Many surgeons continue to advocate the two-stage tissue expander reconstruction due to concerns about skin flap viability and risk of implant failure. Use of TE allows the mastectomy skin flap to heal without undue tension and risk of necrosis.

Two-stage tissue expander reconstruction is an option for women who wish to achieve larger cup size after breast reconstruction (**Figures 26 and 27**). The expander is replaced with a definitive implant as a second operation after completion of adjuvant therapy (such as chemotherapy). It is possible to deliver radiotherapy in women with tissue expanders or implants without compromising treatment. Patients need to be counselled about the increased risks of wound breakdown, implant infection and reconstruction failure in this setting. Use of adjustable expander-implants with a mini-remote port placed outside the radiotherapy field is helpful in reducing CT artefact during planning. There is a wide variation in the delivery of radiotherapy depending on centres.



**Figure 26.** Right two-stage TE and left prophylactic TE reconstruction.





**Figure 27.** Final result replacement left TE with implant.

Many radiation oncologists are reluctant to deliver treatment in the presence of tissue expanders with integrated ports due to the large area of the metal backing in the port, uncertainty about treatment delivery in the area and concerns with raised temperatures and skin burn from treatment. Despite the higher risks, two-stage TE serves as a bridge to definitive reconstruction after completion of radiotherapy and helps preserve the mastectomy skin flap.

In patients who have not had radiotherapy, minor adjustments in the pocket or IMF is achievable in the second stage, but the basic footprint of the reconstruction is designed at the primary operation. Patients should be measured carefully in the clinic prior to surgery as a guide to ordering appropriate sized implants.

Newer technology such as SPY *Elite* system for intraoperative monitoring of skin flap viability and vascular supply and use of newer diathermy devices such as PlasmaBlade (Medtronic plc. ®), which ensures lower tissue temperatures during dissection, can help minimise the risk of skin flap necrosis. Basic surgical principles of gentle tissue handling, avoiding undue traction of the skin flap or use of traumatic instruments at the skin edges, keeping the patient warm perioperatively, avoiding unnecessarily thin mastectomy skin flaps, resting the flap regularly and ensuring tension-free closure of the skin over the implant reconstruction; are simple ways to avoid skin flap necrosis.

## 6. Nipple-sparing and skin-sparing mastectomy

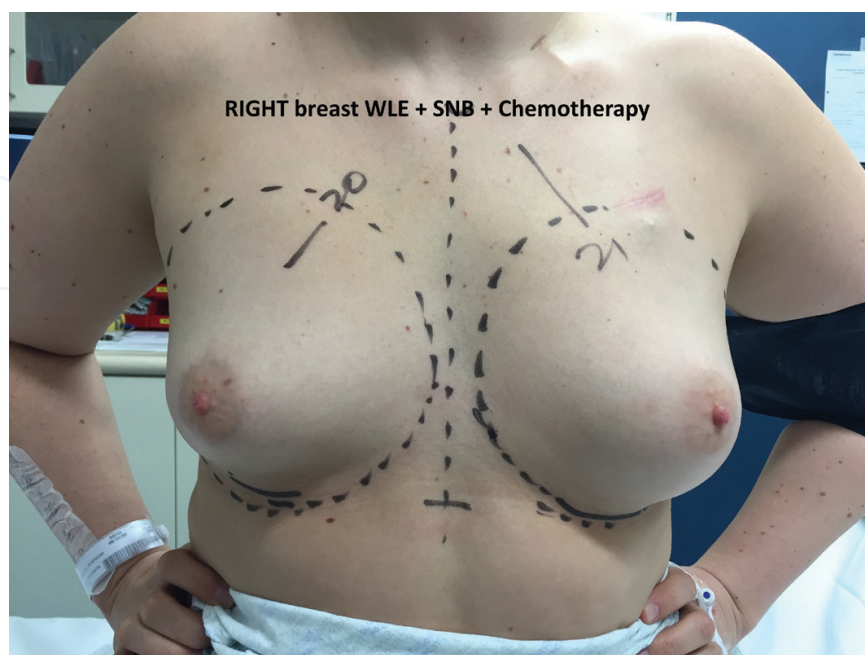
The safety of nipple-sparing mastectomy, depending on tumour location, has been adequately established for both in situ and early invasive breast cancer [28]. Careful preoperative assessment to ensure adequate clearance of the skin and nipple from the tumour site helps to ensure reasonable margins and reduce the risk of recurrence.

Skin-sparing mastectomy is a simpler option in central tumours involving the NAC (**Figure 26**). This is also the commonest approach utilised by general breast surgeons when undertaking combined procedures with their plastic surgery colleagues. The volume of skin excised and scar placement is often dictated by the plastic surgeon. Upfront sentinel node biopsy is carried out as a separate operation to accurately stage the axilla, prior to any reconstruction. If the axillary nodes are involved with metastatic cancer, patients are more likely to require post-operative radiotherapy. In this situation, plastic surgeons may decline immediate implant or autologous reconstruction such as LD or DIEP flap, due to poor aesthetic outcomes and higher reconstruction failure rates after radiotherapy [29, 30].

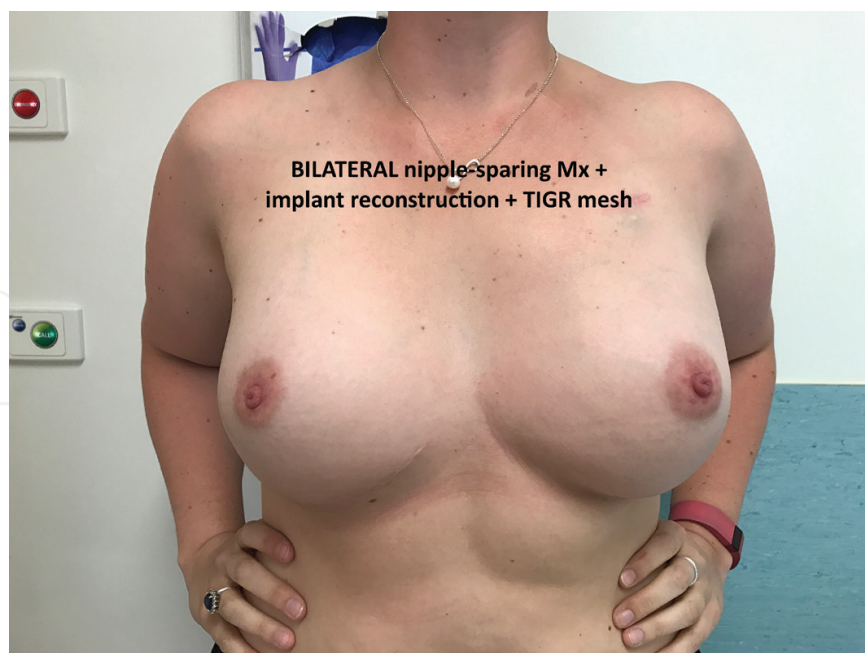Nipple-sparing mastectomy with direct-to-implant reconstruction in the immediate setting is a safe option in experienced hands and avoids the need for a second procedure (**Figures 28 and 29**).

The IMF incision confers adequate access for undertaking mastectomy, axillary surgery and placement of mesh for lower pole support of the implant. Temporary sizers help to determine the optimal implant size and confirm tension-free wound closure. This is an important step as the mastectomy skin envelope should drape the implant rather than stretched across it. The mastectomy skin flap relies on the fine sub-dermal capillaries for its blood supply. This could potentially be compromised with excessively large implants and tight closure of the IMF and result in skin flap necrosis.

Gentle tissue handling, avoiding excessive forceful retraction and preserving the subcutaneous fat layer during mastectomy, are some of the essential steps in preserving the integrity of the mastectomy skin flap. Poor technique is probably the commonest cause for skin flap necrosis and is often reflective of inadequate training and failure to adhere to basic principles outlined above. The product often gets blamed for inferior outcomes in some of the online publications.



**Figure 28.** Post-neoadjuvant chemo BL nipple-sparing mastectomy.



**Figure 29.** Six months after retropectoral implant reconstruction and TIGR mesh.

A single drain is left in the space between the skin flap and the mesh to remove the seroma following mastectomy. The drain is left in until the daily output slows down to approximately 30 ml/day. Build-up of seroma can cause additional tension along the wound edge or affect circulation of the skin flap and must be monitored carefully in the early post-operative period. Seroma formation is much lower with TIGR mesh compared to some ADM's in the author's own presented series [24].

Careful patient selection is important and direct implant reconstruction is best avoided in smokers and high-risk candidates such as diabetics and women with raised BMI. It is essential to have a well-trained, dedicated breast care nurse who is qualified in wound care management. Educating patients about postoperative recovery and precautions about physical activities in the initial months after surgery helps ensure good cosmesis and minimises the risk of wound-related complications.

## **7. Skin-reducing mastectomy, with or without nipple preservation**

Nipple-sparing mastectomy is usually carried out via the IMF approach in small- to medium-sized breasts. It is possible to achieve nipple-sparing mastectomy in larger patients who wish to remain the similar size, via the same approach. In younger patients, some degree of skin contraction is achievable but decline in collagen levels with normal ageing process can result in redundant skin flaps.

Most large breasted women, however, are keen to achieve a smaller reconstructed breast volume and skin-reducing mastectomy techniques can be used with immediate implant reconstruction, with or without nipple preservation. Patients need to be cautioned about

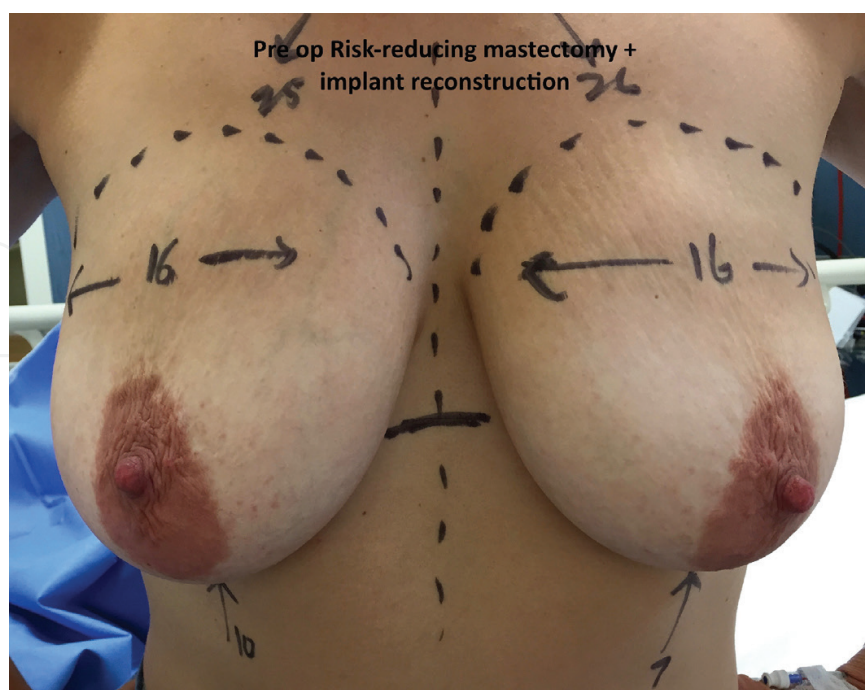


a higher than average risk of nipple necrosis with complex surgery. A skin reducing wise-pattern mastectomy using bi-pedicle dermal flap to maintain vascular integrity of the NAC is described by the author and recently accepted for publication (**Figures 30 and 31**). This technique is a variation of the previously published modified Letterman technique [31] and early results of the author's series were presented as poster at the Leura 8 Conference in Sydney 2016.

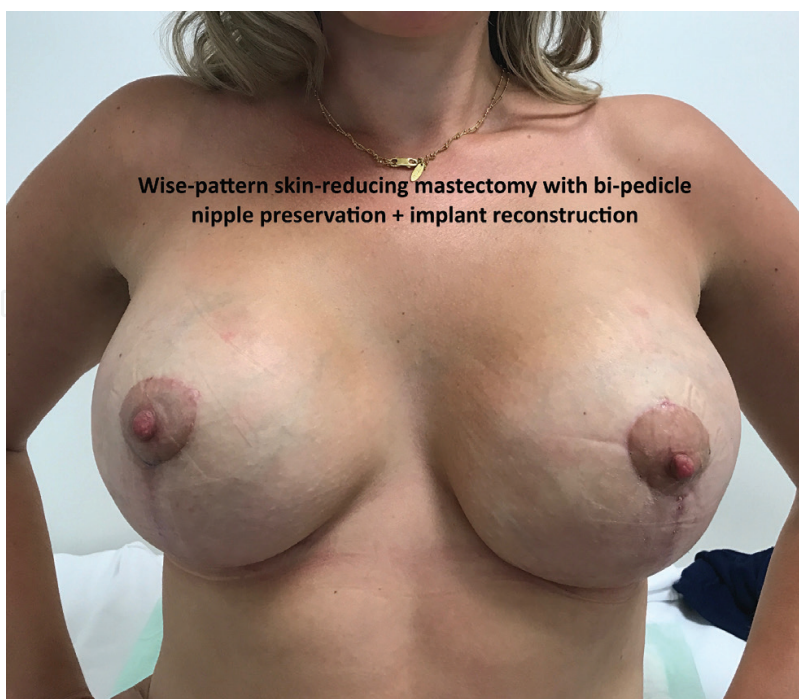This technique can be used in large breasted women for immediate implant-based and autologous reconstruction. It is also possible to use this technique for revision surgery to address any redundant skin flap after previous implant reconstruction. The bi-pedicle dermal flap provides variable length for adjusting the nipple height to the desired position based on the final breast volume and maintains dual vascular supply to the NAC. The dermal flap also protects the incision site from the underlying implant and mesh and minimises risk of implant infection or reconstruction failure.

Tension-free closure of the wound helps reduce pressure on the skin flap and NAC from the underlying implant and protects the fine sub-dermal capillaries supplying the skin flap following mastectomy (**Figure 32**). Use of drains to anticipate any seroma formation and post-operative swelling also helps mitigate the additional risk at the suture line and viability of the NAC.

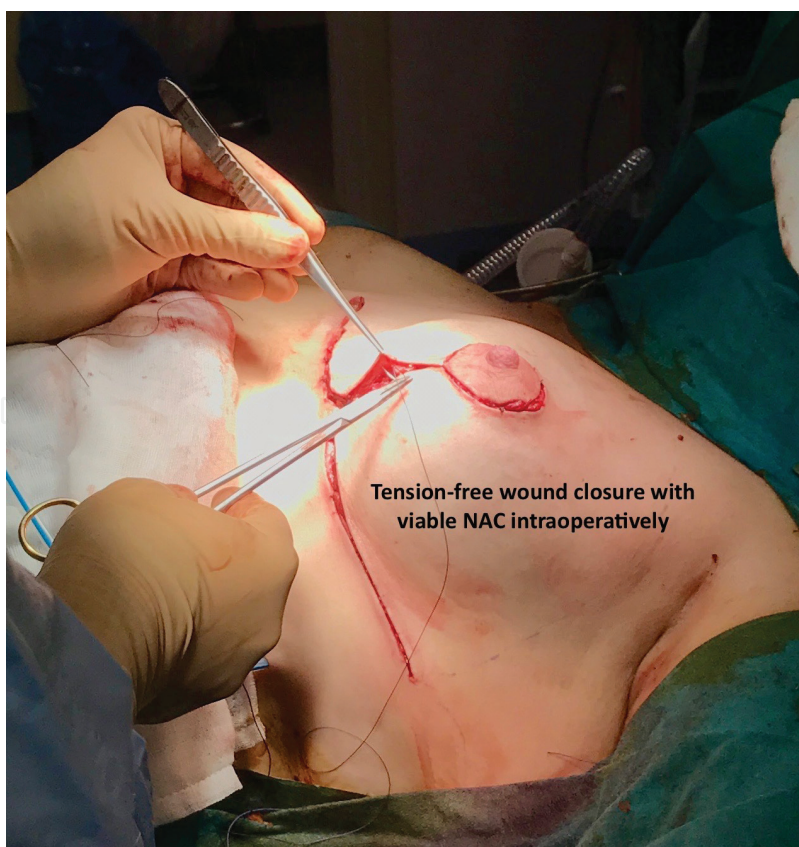
*Goldilocks mastectomy* with implant reconstruction, using a wise-pattern skin incision and dermal flap for lower pole support has been previously described. The nipple vasculature is maintained on the superior pedicle only and is best avoided in older patients or high-risk women such as smokers, diabetics and raised BMI [32].



**Figure 30.** Pre-operative skin-reducing mastectomy.



**Figure 31.** Wise pattern skin-reducing nipple-sparing mastectomy using bi-pedicle dermal flap and implant reconstruction with TIGR mesh.



**Figure 32.** Viable NAC at time of skin closure.



## 8. Silicone versus saline implants

The first silicone implants used in breast surgery were designed in 1961 by Thomas Cronin and Frank Gerow, two American Plastic surgeons. Prior to this, a variety of products were used to fill the cavity, including the practice of injecting silicone into the breast tissue in the 1950s and 1960s. Over 50,000 women in the US who underwent this procedure ended up with silicone granuloma and hardening of the breast and many even requiring mastectomy. Early designs of these implants caused significant capsular contracture, a condition due to the host tissue creating a shell around the implant which gets progressively hard and uncomfortable. The Baker classification of grading capsular contractures from I to IV is often used as standardised measure of assessing the degree of hardness and aesthetic outcome [33]. The true incidence of capsular contracture after breast implant augmentation is quoted between 8–15%, although the incidence following breast reconstruction may be higher. The exact cause of capsular contracture is not known and range from biofilm secondary to subclinical infection and inflammatory foreign-body type reaction. The incidence of capsular contracture has been found to be less with textured implants compared to smooth implants.

Early manufacturers found the use of polyurethane foam coating on the shell of the implants helped minimise the risk of capsular contracture. This practice was discontinued due to concerns of potential health risk from 2,4-toluenediamine (TDA), a carcinogenic by-product of the chemical breakdown of polyurethane. The FDA banned the use of silicone implants in 1992 during which time saline implants were the predominant prosthetic device used in America. Coincidentally, silicone implants continued to be used across Europe and Australasia despite the FDA ban. Saline implants were first designed in France and introduced in 1964 as a medical prosthetic device but caused more wrinkling with higher rates of capsular contracture and accelerated lower pole stretch, making it less desirable as a reconstruction option post mastectomy. The FDA eventually lifted its ban in 2006 following extensive research confirming safety of silicone implants.

Silicone implants came under media scrutiny again in 2017 following reports of **Breast implant associated–Anaplastic Large Cell Lymphoma (BIA-ALCL)**. This has resulted in an almost knee-jerk response to revert back to saline implants in some centres. The actual risk of BIA-ALCL is very low and believed to be related to heavily textured implants, although few cases have been reported with smooth implants as well. As of September 2017, 409 cases of BIA-ALCL have been reported worldwide with 14 deaths. Current risk of developing BIA-ALCL with silicone implant use is quoted between 1: 30,000 and 1: 50,000. Manufacturers continue to design newer and lower textured implants in an attempt to counter the growing public concern around ALCL. The historic issues with saline implants of increased capsular contracture, rotation/flipping of the implant, rupture and migration remain with its use and could result in increased revision rates.

Decision regarding saline or silicone implants should be based on clinical indications, rather than fear of ALCL associated with textured implants. Patients should be advised about the small risk of BIA-ALCL and that the majority of cases are diagnosed early. Typical presentation is a sudden build-up of fluid around the implant and 9–13% of delayed seroma may be ALCL related. The timeframe for ALCL is usually 15 months to 5 years post implant surgery.

Ultrasound-guided aspiration of the fluid tested for CD-30 on IHC, is the definitive diagnostic test for BIA-ALCL. PET scan is recommended to stage the patient and in early stage disease, explantation with complete en-bloc capsulectomy including the posterior wall, combined with excision biopsy of lymph nodes is recommended. Due to the rarity of this condition, the Australasian Society of Plastic Surgeons (ASPS) advice that only few dedicated labs undertake the test and only specialist surgeons perform the operation to ensure good outcomes for patients. Patients should be reassured that stages I and II are completely curable. Chemotherapy in advanced cases and CD-30 targeted therapy in refractory cases have shown encouraging results. Standardised guidelines for the diagnosis and management of BIA-ALCL have been published by NCCN in 2016 [34].

Choice of anatomical versus round implants requires careful assessment of the patient's body habitus, chest wall shape and width, native breast shape and discussion regarding the desired final outcome. In a cancer setting, it is worth being cautious about having a *carte blanche* approach to implant options. With medium sized breasts, patients should be encouraged to remain approximately the same cup size and additional cleavage is achievable with round versus anatomical implants. Patients should be cautioned about using the appropriate implant size as determined by the mastectomy skin envelope, to avoid complications of skin flap necrosis or wound breakdown (Section 6).

It is advisable to order a range of implants to choose from at the time of surgery. Use of sizers intraoperatively can help determine ideal sized implants to ensure tension-free closure of the wound. Surgeons embarking on their career in oncoplastic breast surgery should become familiar with the range of commercially available implants in terms of height, width and profile.

## 9. Revision surgery and lipomodelling

Capsular contracture is a well-documented risk associated with implant reconstruction and patients should be cautioned prior to surgery. The risk of capsular contracture is higher with saline and smooth implants compared to textured or polyurethane-coated implants and in sub-muscular placement. The incidence is approximately 10–15% and is the commonest reason for revision surgery. Increasing role of lipomodelling to help reduce the risk of capsular contracture and address contour defects from previous surgery can minimise the extent or complexity of revision surgery [35, 36]. Patients should be advised that lipomodelling is different from liposuction and should not expect to achieve significant weight reduction after this procedure. There is a limited volume of lipofilling that can be achieved during revision surgery, taking care to avoid excess tension and risk of fat necrosis. Safety of fat grafting has now been adequately established and serves to improve vascularity to the thin mastectomy flaps, especially after previous radiotherapy.

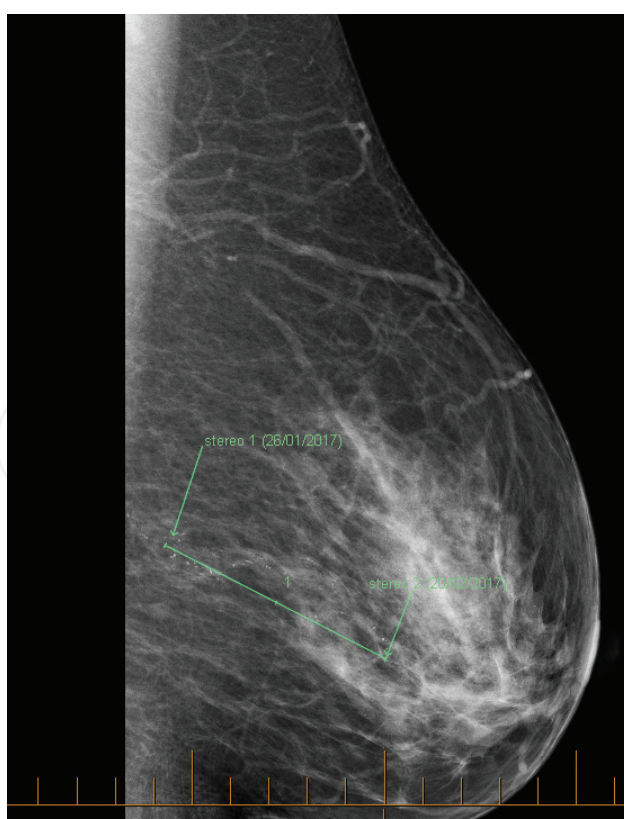
It is important to set patient expectations at the outset and emphasise that the aim of oncoplastic breast surgery is not to achieve perfection, but rather obtain as close to a normal appearing breast as possible. Patients should also be cautioned that each revision surgery carries additional risks to the native skin flaps and that the aesthetic outcome may not be as good as the initial results in some cases.

## 10. Patient choice versus treatment options

Before the advent of oncoplastic breast surgery, limited options between WLE and simple mastectomy made surgical consultations around breast cancer treatment relatively simple. The ability to offer a wide range of surgical options does not warrant outlining the entire list to patients during their initial visit. This is particularly relevant when patients are struggling with heightened anxiety around their cancer diagnosis. There is good evidence to suggest that patients only retain a fraction of the complex discussion undertaken in a doctor's office. It requires experience and skill to navigate the complexity of information offered during the initial consultation and to gauge the patient's level of understanding.

It is important to actively enquire if the patient is satisfied with the shape and size of her breasts at the time of diagnosis, even before instigating any discussions around OPS. In this example, a 67-year-old patient with a new screen-detected 80 mm area of DCIS in the upper outer quadrant was recommended mastectomy with sentinel node biopsy by the MDT (**Figure 33**).

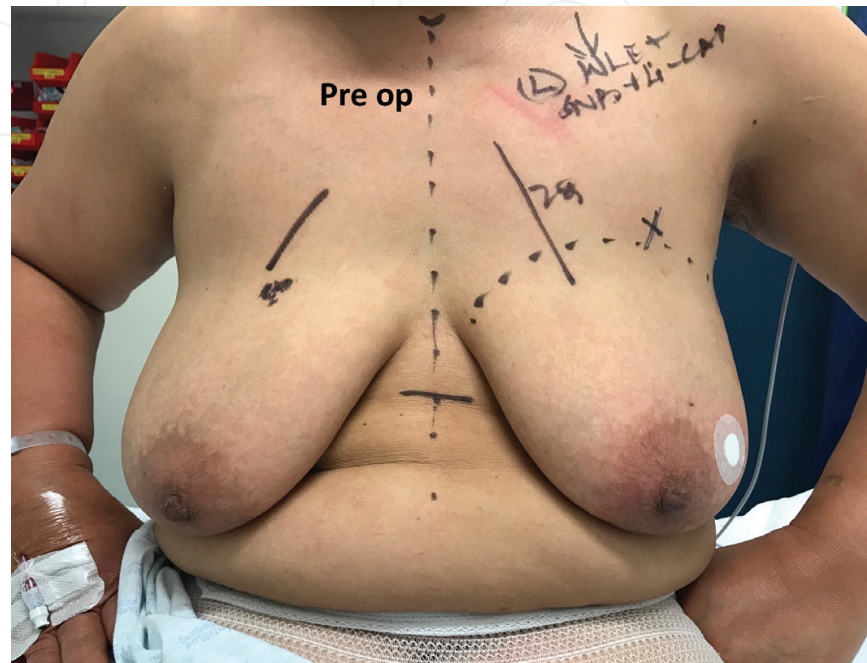
The patient was keen on immediate reconstruction but raised BMI with ptotic native breast and social circumstances made implant or autologous reconstruction challenging with need for symmetrising contralateral procedure (**Figure 34**). Further discussion with the patient and option for extended WLE with SNB and immediate Li-CAP autologous dermal-adipose



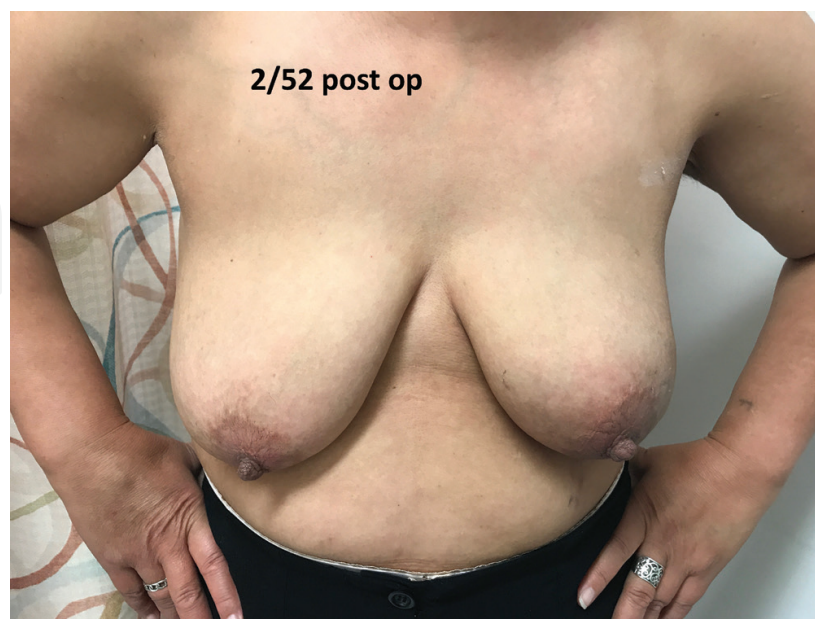**Figure 33.** Mammogram with DCIS.



flap for volume replacement served as the ideal option in this patient. She was well enough to be discharged after 2 days in hospital without any delay in adjuvant radiotherapy. The lateral scar remains hidden within the bra line with good functional status, low donor site morbidity, return to normal activities and high satisfaction rates with aesthetic outcomes (Figure 35).



**Figure 34.** Pre-op left breast DCIS.

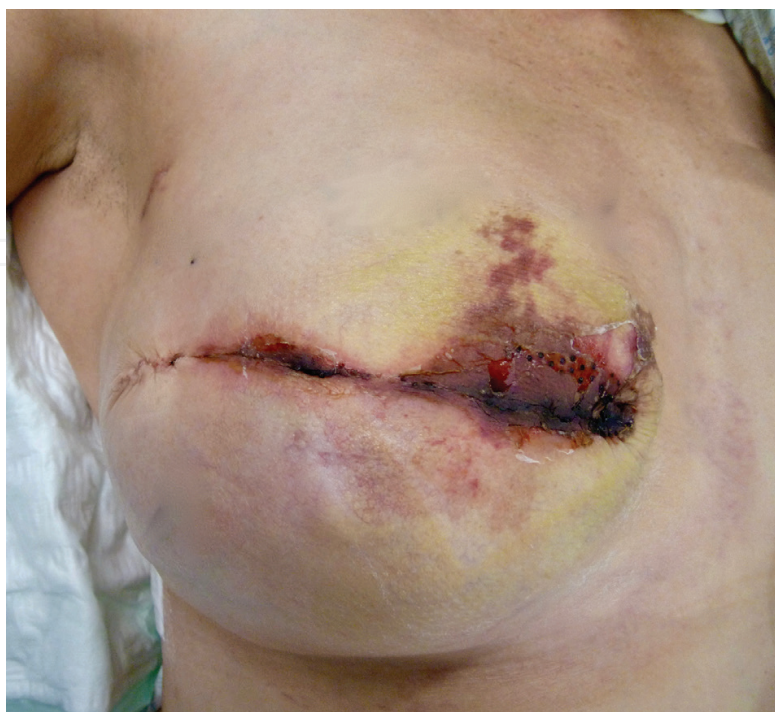

**Figure 35.** Post-op extended WLE with Li-CAP volume replacement.

Choice of reconstruction options may be limited by patient factors like smoking status. Implant and autologous reconstruction such as DIEP are not routinely offered to women who smoke, due to unacceptably high rates of wound complications and reconstruction failure. There are many centres where implant reconstruction is routinely offered to women who smoke, but patients need to be clearly informed about the high risk of wound related complications and implant failure. Smoking causes vasoconstriction with altered bacterial flora secondary to tissue hypoxia and is believed to be responsible for the poor wound healing (**Figure 36**). This could negatively impact on younger patients due to delays in adjuvant chemotherapy.

Raised BMI is an independent risk factor for higher seroma rates, increased wound infection and anaesthetic related issues. Implant reconstruction in larger women can be difficult due to limited choices of implants to accommodate the wide chest wall dimension. The shape of the reconstructed breast is governed by the shape and size of implant and symmetrising surgery is often required to address the large and ptotic contralateral breast. The risks for wound complications are higher if this is combined with cancer surgery and could delay adjuvant therapy. In these patients, the autologous Li-CAP perforator flap or Goldilocks mastectomy (Section 2.3.1) serves as a useful and safer alternative for immediate reconstruction after mastectomy and appears to tolerate radiotherapy well. Patients need to be cautioned about prolonged seroma formation with both these options.

There has been a global increase in the incidence of contralateral prophylactic mastectomy (CPM) in the last decade and has been often labelled the 'Angeline Jolie effect'. Over the same timeframe, a well-cited Wall Street Journal article from July 2015 has resulted in increasingly number of women taking ownership for their treatment and demanding a double mastectomy [37]. Anxiety around perceived cancer recurrence, poor diagnostic yield with standard

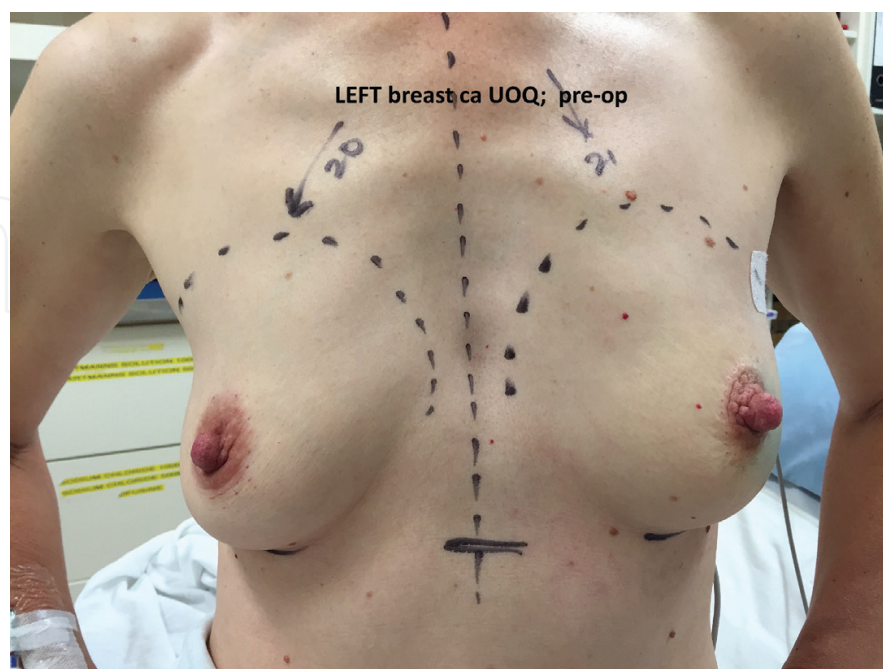


**Figure 36.** Smoking-related complication.

imaging in lobular cancers, family history and discomfort from multiple biopsies and repeated mammograms; are some of the reasons for women seeking CPM. More recently, the surgical community has been criticised for ‘bowing down’ to patient request for double mastectomy when diagnosed with a new cancer. Some women may feel strongly about undergoing one operation, which could help reduce anxiety around repeated imaging and biopsy. It is important to carefully understand the individual patient’s reasons for considering CPM. There is good evidence that CPM does not confer survival benefit and risk of contralateral breast cancer for the vast majority of patients is relatively low. Patients need to be clearly explained about the higher risk of wound related complications, delayed recovery and impact on adjuvant treatment with low benefit in terms of survival and recurrence. Despite this, if they continued to feel strongly about bilateral mastectomy with or without reconstruction, it would be reasonable to offer them the option of CPM (**Figures 37 and 38**).

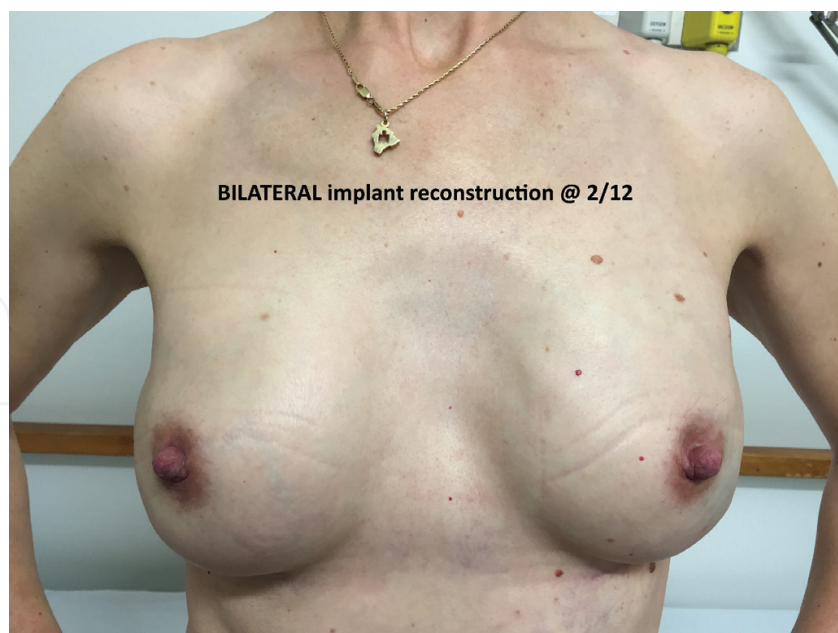It is important to clearly document all aspects of preoperative discussions in the clinical records due to potential medicolegal implications.

There is potential for ‘clinician bias’ with even experienced surgeons which could alter the direction of the consultation. This could be due to preconceived ideations about patient body image, based on their appearance, educational background and socioeconomic status. Conversely, young women with large tumours are still subject to simple mastectomy without reconstruction in many hospitals around New Zealand and Australia; even in those with good clinical response to neoadjuvant chemotherapy. The rationale for this practice is based on historic concerns about potentially leaving disease behind, treatment delays or reduced effectiveness of adjuvant radiotherapy in the context of immediate reconstruction. This bias towards mastectomy genuinely stems from the sense of ‘duty of care’ with greater focus on the treatment and its outcome, rather than the psychological impact of mastectomy on



**Figure 37.** Pre-op left breast cancer.





**Figure 38.** Left mastectomy and CPM with implant reconstruction.

a young woman. Historic data from the National Screening Unit in the UK found that 30% of women undergoing mastectomy suffered from depression after treatment; equally 30% of women undergoing breast conservation had anxiety about recurrent cancer. The emphasis therefore should not be about avoiding a mastectomy but rather considering immediate reconstruction options in those who need mastectomy. Reverse sequencing with upfront radiotherapy in young patients is a relative new concept, which allows mastectomy with immediate autologous reconstruction, such as LD flap with implant, without compromising aesthetic outcome.

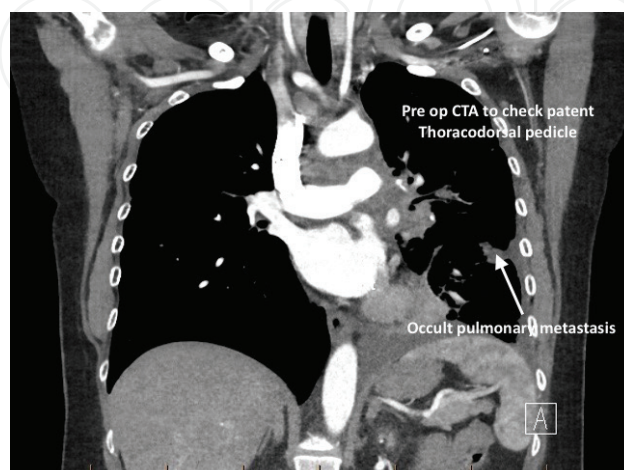
Increasing use of neoadjuvant chemotherapy and neoadjuvant endocrine therapy to down-stage disease, provides adequate time to plan surgery for both patients and the treating surgeon [38, 39]. This allows time to organise genetic testing when indicated and an opportunity to improve patient health status, e.g., smoking cessation, weight loss to achieve target BMI and additional sessions with the clinical psychologists. In women with normal BMI and in whom post-operative radiotherapy is indicated, use of tissue expander as an immediate-delayed reconstruction, is advocated by the MD Anderson group and serves as a bridge to definitive reconstruction whilst preserving the mastectomy skin flap. Women are able to wake up from surgery without having to deal with the trauma of mastectomy.

The traditional approach of delaying reconstruction for several months (sometimes years) after initial cancer treatment can be detrimental to the psychosocial well-being of women struggling with their cancer diagnosis. In women with raised BMI, trying to lose weight can be a challenge and many centres would not offer delayed reconstruction unless patients achieved their target weight. There are limited options viz. DIEP for delayed reconstruction in women who have had post mastectomy radiotherapy. Some plastic surgeons would consider two-stage TE reconstruction after radiotherapy, but the results are variable due to limited skin and muscle expansion with high rates of reconstruction failure.

Delayed LD flap with implant is a good option in patients who have had post mastectomy radiotherapy with less donor site morbidity compared to other forms of reconstruction. Any symmetrisation option for the native breast is probably best deferred for at least 6 months to allow the LD flap to settle and offers the opportunity to correct any contour defects with lipofilling at the time of the second procedure. Preoperative CT angiogram is recommended in the delayed setting to confirm patent thoracodorsal pedicle prior to lifting the LD flap. Simple bedside examination by getting the patient tense the latissimus dorsi muscle would suggest intact pedicle and formal imaging can help delineate the anatomy adequately. The CTA occasionally picks up occult lung metastasis in patients waiting for delayed reconstruction (**Figure 39**).

Breast reconstruction following mastectomy is a complex decision and requires detailed discussion with patients to ensure adequate understanding about the complexity of surgery. It is important to ensure patient compliance with post-operative protocols to help minimise wound-related complications and potentially poor outcome from reconstruction failure. Oncoplastic breast surgeons can offer a broad range of treatment options suitable for the individual patient based on cancer biology, proposed treatment plan and patient factors, such as breast shape and density, smoking history, BMI and other medical co-morbidities. It is recommended to have a minimum of two discussions prior to any reconstructive surgery with adequate clinic time allocated to ensure detailed discussion and patient understanding about options and operative choices. Use of detailed information leaflets to suit the organisation serves as a useful adjunct to the discussion, which patients can read at home in a less stressful environment. Additional consultations offer patients the opportunities to seek clarification about the proposed operation and the surgeon can revisit the potential risks and complications to ensure informed consent.

An experienced breast care nurse familiar with various oncoplastic procedures is invaluable in helping patients with preoperative counselling and decision-making. In some patients, this process can take a few weeks and may require input from clinical psychologists. This helps confirm patient's understanding about various treatment options available, ensure decision-making has not been unduly influenced or coerced, and minimises the risk of 'decision-regret' at a later stage.



**Figure 39.** CTA showing occult pulmonary metastasis.

With the rapid global uptake of OPS, there remains a real danger of potentially worse patient outcome due to poor technique, improper patient selection or decision making. This is one specialty where good surgical skills are essential and inadequate training reflects on the operative outcomes with results which are glaringly obvious to both patients and clinicians.

There are well-established OPS training programmes in the UK, and post-fellowship trainees in Australasia are encouraged to undertake at least 2–3 years of additional clinical training in accredited centres. The additional training serves to up-skill their technical prowess and more importantly, learn the complex process of patient selection and the art of good communication. The rationale for oncoplastic breast surgery as an integral part of all breast cancer surgery has been eloquently detailed in a review article [40].

## 11. Conclusion

In summary, oncoplastic breast surgery has established a firm place in the global fight against breast cancer. Patients should be offered the appropriate range of surgical treatment options instead of the conventional two-operation strategy, prevalent for the past 40 years. Clinical discussions are therefore more complex and additional time and expertise is required to help patients with decision-making. Having a well-trained and experienced breast care nurse is invaluable in a busy oncoplastic breast practice. A multidisciplinary team approach is an integral part of modern cancer management with early contribution of clinical psychologists in selected cases. Developing an oncoplastic breast surgery practice from the ground up, can be time-consuming and challenging. It is possible to establish a modern oncoplastic breast surgical practice despite the usual constraints of a public health system and help women achieve a satisfactory cosmetic outcome combined with safe oncological treatment of their breast cancer.

Surgical residents should be trained to a high standard and accreditation of oncoplastic breast surgical training is crucial to avoid repeating the historical mistakes of the laparoscopic era. The Royal Australasian College of Surgeons has recently set up an oncoplastic breast surgery master's programme for post-fellowship trainees. This will become mandatory to help standardise clinical knowledge, technical expertise and competency levels with peer review and audit. Monash University, in Melbourne, Australia, has been tasked with monitoring all breast implants used in reconstructive surgery to ensure a national registry service for breast surgical prosthetic devices.

Whilst a detailed description of oncoplastic breast surgery has not been possible, this chapter hopes to offer a broad overview of modern surgical practice with emphasis on implant-based reconstruction.

## Acknowledgements

The author wishes to acknowledge the continued dedicated efforts of Maria Winter, Oncoplastic Breast Care Nurse, Department of Surgery, Christchurch Hospital, Christchurch, New Zealand.



Her continued support and expertise has made it possible to establish Oncoplastic Breast Surgery in Christchurch since 2009. The author also would like to thank all her patients for allowing use of clinical photographs and details of their diagnosis for this book chapter.

## Conflict of interest

There are no conflicts of interests to declare.

## Author details

Josie Todd<sup>1,2,3,4,5\*</sup>

\*Address all correspondence to: [josie.todd@cdhb.health.nz](mailto:josie.todd@cdhb.health.nz)

1 Department of Surgery, CDHB, Christchurch, New Zealand

2 Royal College of Surgeons of Edinburgh, UK

3 University of Otago, New Zealand

4 Health Disability and Ethics Commission (HDEC), New Zealand

5 Accident Compensation Corporation (ACC), New Zealand

## References

- [1] Halsted W. The results of operations for the care of cancer of the breast performed at the Johns Hopkins hospital from June, 1889, to January, 1894. *Annals of Surgery*. 1894;**20**(5):497-555
- [2] Fisher B, Anderson S, Bryant J, et al. Twenty-year follow-up of a randomized trial comparing total mastectomy, lumpectomy, and lumpectomy plus irradiation for the treatment of invasive breast cancer. *The New England Journal of Medicine*. 2002;**347**:1233-1241. [PubMed: 12393820]
- [3] Veronesi U, Cascinelli N, Mariani L, et al. Twenty-year follow-up of a randomized study comparing breast-conserving surgery with radical mastectomy for early breast cancer. *The New England Journal of Medicine*. 2002;**347**:1227-1232. [PubMed: 12393819]
- [4] Clough KS et al. Improving breast cancer surgery: A classification and quadrant per quadrant atlas for oncoplastic surgery. *Annals of Surgical Oncology*. 2010;**17**(5):1375-1391. DOI: 10.1245/s10434-009-0792-y
- [5] McCulley S, Macmillan RD. Planning and use of therapeutic mammoplasty—Nottingham approach. *British Journal of Plastic Surgery*. 2005;**58**:889-901

- [6] Kronowitz SJ. Delayed-immediate breast reconstruction: Technical and timing considerations. *Plastic and Reconstructive Surgery*. 2010;**125**(2):463-474
- [7] Saini KS et al. Role of the multidisciplinary team in breast cancer management: Results from a large international survey involving 39 countries. *Annals of Oncology*. 2012;**23**(4): 853-859
- [8] Halkett G et al. The role of the breast care nurse during treatment for early breast cancer: The patient's perspective. *Contemporary Nurse*. 2006;**23**(1):46-57
- [9] Litiere S et al. Breast conserving therapy versus mastectomy for stage I–II breast cancer: 20-year follow-up of the EORTC 10801 phase 3 randomised trial. *Lancet Oncology*. 2012;**13**(4):412-419
- [10] Al-Ghazal SK, Blamey RW, Stewart J, Morgan AAL. The cosmetic outcome in early breast cancer treated with breast conservation. *European Journal of Surgical Oncology*. 1999;**25**(6):566-570. DOI: 10.1053/ejso.1999.0707
- [11] Fernando C, Todd J. Why scar placement is important for women undergoing WLE for breast cancer: Evaluating cosmetic outcome in the breast unit with use of clinical photographs and patient feedback questionnaire. *ANZ Journal of Surgery*. 2017;**87**(S1):6-14
- [12] Benelli L. A new periareolar mammoplasty: The “round block” technique. *Aesthetic Plastic Surgery*. 1990;**14**(2):93-100
- [13] Currie A et al. Using therapeutic mammoplasty to extend the role of breast-conserving surgery in women with larger or ptotic breasts. *Annals of the Royal College of Surgeons of England*. 2013;**95**(3):192-195
- [14] McCulley SJ et al. Therapeutic mammoplasty for centrally located breast tumours. *Plastic and Reconstructive Surgery*. 2006;**117**(2):366
- [15] Hamdi M, Van Landuyt K, de Frene B, Roche N, Blondeel P, Monstrey S. The versatility of the inter-costal artery perforator (ICAP) flaps. *Journal of Plastic, Reconstructive & Aesthetic Surgery*. 2006;**59**(6):644-652. DOI: 10.1016/j.bjps.2006.01.006
- [16] More Women Choose Breast Reconstruction after Mastectomy. *Medicalxpress.com> Surgery*. 13 Oct 2017
- [17] Schmauss D et al. Breast reconstruction after mastectomy. *Frontiers in Surgery*. 2015;**2**:71
- [18] Yu P. Breast reconstruction at the MD Anderson Cancer Centre. *Gland Surgery*. 2016;**5**(4):416-421. DOI: 10.21037/gs.2016.05.03
- [19] Carrasco-López C, Ibañez JFJ, et al. Anterior intercostal artery perforator flap in immediate breast reconstruction: Anatomical study and clinical application. *Microsurgery*. 2017;**37**(6):603-610. DOI: 10.1002/micr.30171 PMID: 28370199
- [20] Hakakian CS, Lockhart RA, Kulber DA, Aronowitz JA. Lateral intercostal artery perforator flap in breast reconstruction: A simplified pedicle permits an expanded role. *Annals of Plastic Surgery*. 2016;**76**(Suppl 3):S184-S190

- [21] Macadam SA, Lennox PA. Acellular dermal matrices: Use in reconstructive and aesthetic breast surgery. *The Canadian Journal of Plastic Surgery*. 2012;**20**(2):75-89
- [22] Mendenhall SD, Anderson LA, Ying J, Boucher KM, Neumayer LA, Agarwal JP. The BREASTrial stage II: ADM breast reconstruction outcomes from definitive reconstruction to 3 months postoperative. *Plastic and Reconstructive Surgery Global Open*. 2017;**5**(1):e1209. DOI: 10.1097/GOX.0000000000001209
- [23] Gaske I et al. Delayed hypersensitivity reaction to acellular dermal matrix in breast reconstruction: The red breast syndrome? *Annals of Plastic Surgery*. 2014;**73**(Suppl 2): S139-S143
- [24] Peek K, Todd J. Does TIGR earn its stripes? – Outcomes of reconstructive breast surgery using long-term absorbable synthetic matrix (preliminary results) Poster presentation at Annual Scientific Congress, Royal Australasian College of Surgeons. *ANZ Journal of Surgery*. 2015;**85**(Suppl. 1):3-13
- [25] Thompson B, Todd J. TIGR mesh-assisted immediate and delayed implant reconstruction following mastectomy and revision surgery: Largest single oncoplastic breast surgeon experience in a regional Centre. *ANZ Journal of Surgery*. 2018;**88**(Suppl 1):12
- [26] Pompei S et al. The use of TIGR matrix in breast aesthetic and reconstructive surgery. Is a resorbable synthetic mesh a viable alternative to acellular dermal matrices? *Clinics in Plastic Surgery*. 2018;**45**:65-73
- [27] Becker H et al. Immediate implant-based prepectoral breast reconstruction using vertical incision. *Plastic and Reconstructive Surgery Global Open*. 2015;**3**(6):e412
- [28] Orzalesi L et al. Nipple-sparing mastectomy: Surgical and oncological outcomes from a national multicentric registry with 913 patients (1006 cases) over a 6 year period. *Breast*. 2016;**26**:75-81
- [29] Fowble B et al. Rates of reconstruction failure in patients undergoing immediate reconstruction with tissue expanders and/or implants and postmastectomy radiation therapy. *International Journal of Radiation Oncology, Biology, Physics*. 2015;**92**(3):634-641
- [30] Kronowitz S. Current status of implant-based breast reconstruction in patients receiving postmastectomy radiation therapy. *Plastic and Reconstructive Surgery*. 2012;**130**(4): 513e-523e. DOI: 10.1097/PRS.0b013e318262f059. PMID: 23018711
- [31] Todd J. Bi-pedicle nipple-sparing mastectomy (modified Letterman technique) and TIGR mesh assisted immediate implant reconstruction, in a patient with Cowden's syndrome. *Gland Surgery*. 2016;**5**(3):306-311
- [32] Ladizinsky DA et al. Breast reconstruction with the Bostwick autoderma technique. *Plastic and Reconstructive Surgery*. 2013;**132**:261-270
- [33] Malahias M et al. A literature review and summary of capsular contracture: An ongoing challenge to breast surgeons and their patients. *International Journal of Surgery Open*. 2016;**3**:1-7



- [34] Clemens M et al. NCCN consensus guidelines for the diagnosis and management of breast implant-associated anaplastic large cell lymphoma. *Aesthetic Surgery Journal*. 2017;**37**(3):285-289
- [35] Breast Reconstruction using Lipomodelling after Breast Cancer Treatment. NICE Interventional Procedures Guidance [IPG417]. Published date: January 2012
- [36] Chan CW, McCulley SJ, Macmillan RD. Autologous fat transfer—A review of the literature with a focus on breast cancer surgery. *Journal of Plastic, Reconstructive & Aesthetic Surgery*. 2008;**61**:1438-1448
- [37] Lagnado L, Doctors D. More women with breast cancer choose double mastectomies. *Wall Street Journal*. 10 July, 2015
- [38] EBCTCG. Long-term outcomes for neoadjuvant versus adjuvant chemotherapy in early breast cancer: Meta-analysis of individual patient data from ten randomised trials. *The Lancet Oncology*. 2018;**19**:27-39
- [39] Cain H et al. Neoadjuvant therapy in early breast cancer: Treatment considerations and common debates in practice. *Clinical Oncology*. 2017;**29**:642-652
- [40] Macmillan RD, McCulley SJ. Oncoplastic breast surgery: What, when and for whom? *Current Breast Cancer Reports*. 2016;**8**:112-117